



شبكة المعلومات الجامعية





شبكة المعلومات الجامعية التوثيق الالكتروني والميكروفيلم



شبكة المعلومات الجامعية

جامعة عين شمس

التوثيق الالكتروني والميكرو فيلم

قسم

نقسم بالله العظيم أن المادة التي تم توثيقها وتسجيلها
على هذه الأفلام قد أعدت دون أية تغيرات



يجب أن

تحفظ هذه الأفلام بعيدا عن الغبار

في درجة حرارة من ١٥-٢٥ مئوية ورطوبة نسبية من ٢٠-٤٠%

To be Kept away from Dust in Dry Cool place of
15-25- c and relative humidity 20-40%

بعض المواقف
 سلطة الخلفه
 Air Shams University
 International Network
 جامعة عين شمس

شبكة المعلومات الجامعية
 @ ASUNET

بالرسالة صفحات لح



شبكة المعلومات الجامعية
@ ASUNET

Surgical Studies on Urine Retention in Male Ruminants

A Thesis

**Presented to the Graduate School
Faculty of Veterinary Medicine, Alexandria University
In Partial fulfilment of the Requirements for the Degree**

Of

Master of Veterinary Sciences

In

((Surgery))

By

Mostafa Ghanem Ahmed Ghanem

(B.V.Sc. Fac. Vet. Med., Alex. Univ., 2007)

((2010))



8 2257

Surgical Studies on Urine Retention in Male Ruminants

Presented by

Mostafa Ghanem Ahmed Ghanem

For the degree of

Master of Veterinary Sciences

In


Surgery

Examiner's Committee

Signature

Prof. Dr. Samy farghaly Ismail

professor & Head of the Dept. of surgery,
Faculty of Veterinary Medicine
Banha University



Prof. Dr. Mostafa Mohamed Kassem

Prof. of surgery & Vice Dean of the Fac. of
Vet. Med.
Alexandria University

Kassem
.....


Prof. Dr. Samir Rashed Nouh

Professor & Head of the Dept. of surgery
Faculty of Veterinary Medicine
Alexandria University

S. R. Nouh
.....


Prof. Dr. Ramadan El-Sayed Abd El-wahed

Professor of surgery
Faculty of Veterinary Medicine
Alexandria University



Dr. Mahmoud Hussein El-Kammar

Associate Professor of surgery
Faculty of Veterinary Medicine
Alexandria University



ADVISOR'S COMMITTEE

Signature

Prof. Dr. Samir Rashed Noh

Professor & Head of the Dept. of surgery,
Faculty of Veterinary Medicine
Alexandria University

S.R. Noh

Prof. Dr. Ramadan El-Sayed Abd El-wahed

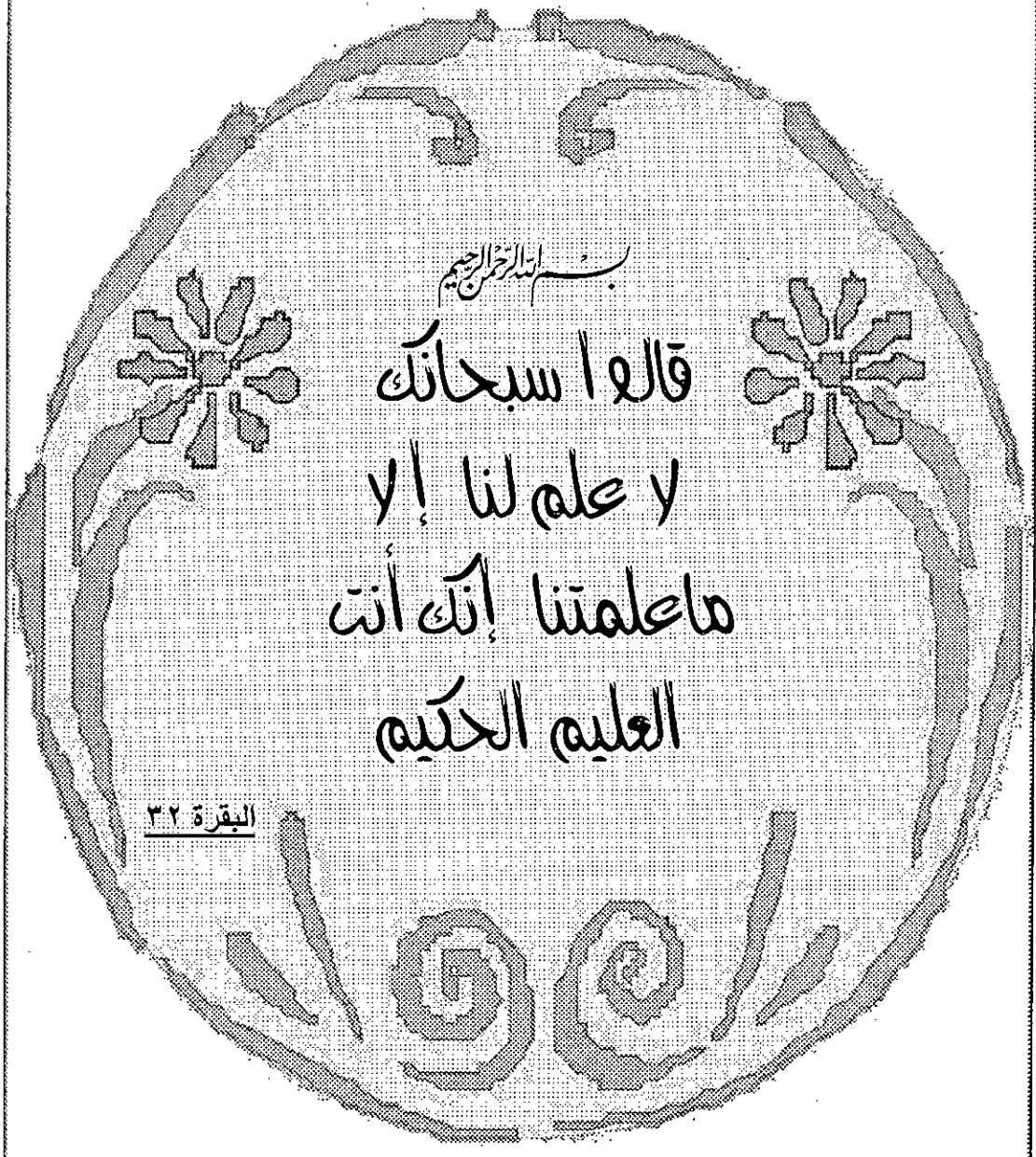Professor of surgery
Faculty of Veterinary Medicine
Alexandria University

Abdelwahed

Dr. Mahmoud Heussin El-kammar

Assistant Professor of surgery
Faculty of Veterinary Medicine
Alexandria University

El. Kammar M. H.



بِسْمِ اللَّهِ الرَّحْمَنِ الرَّحِيمِ

قَالَ اَسْبِحَانِكَ
يَا عَلِمَ لَنَا يَا
مَا عَلَّمْتَنَا إِنَّكَ أَنْتَ
الْعَلِيمُ الْحَكِيمُ

البقرة ٣٢

Dedication

TO

My family

Contents

<i>SUBJECT</i>	<i>PAGE</i>
Introduction	1
Review of literature	3
<ul style="list-style-type: none"> • Incidence s of urolithiasis: • causes of urolithiasis: • Diagnosis o urolithiasis: <ul style="list-style-type: none"> ➤ Clinical examination: ➤ Serum biochemical changes: ➤ Ultrasonographic finding: ➤ Catheterization: • Treatment of urolithiasis: <ul style="list-style-type: none"> ➤ Medical treatment. ➤ Surgical treatment. <ul style="list-style-type: none"> ✓ Urethral process amputation. ✓ Perineal urethrostomy and urethrotomy. ✓ Surgical tube cystotomy. ✓ Percutaneoustube cystotomy ✓ Bladder marsupialization. ✓ Buccal mucosal grafting. 	3
Materials and Methods	24
Group (I): <ul style="list-style-type: none"> ➤ Direct penile ligation at the distal bend of the sigmoid flexure. ➤ Perineal urethrostomy. ➤ Surgical tube cystotomy. ➤ Bladder marsupialization. 	24

<ul style="list-style-type: none"> ➤ PhysioBiochemical analysis. ➤ Ultrasonographic examination. <ul style="list-style-type: none"> ✓ UltraSonographic examination of goat's kidneys. ✓ Ultrasonographic examination of the bladder and caudal abdomen. <p>Group (II):</p> <ul style="list-style-type: none"> ➤ Clinical examination ➤ Surgical intervention <ul style="list-style-type: none"> ✓ Urethral process amputation ✓ Perineal urethrostomy ✓ perineal urethrostomy and cystorraphy via laparotomy ✓ Bladder marsupialization and cystorraphy via laparotomy ✓ Urethral fistulation ➤ Postoperative care 	
Results	47
<p>Group (I):</p> <ul style="list-style-type: none"> ➤ direct penile ligation at the distal bend of the sigmoid flexure . ➤ Perineal urethrostomy. ➤ Surgical tube cystotomy. ➤ Bladder marsupialization. ➤ PhysioBiochemical analysis. ➤ Ultrasonographic examination. <ul style="list-style-type: none"> ✓ UltraSonographic examination of goat's kidneys. ✓ Ultrasonographic examination of the bladder and 	

caudal abdomen.

Group (II):

➤ **Clinical examination**

➤ **Surgical intervention**

✓ Urethral process amputation

✓ Perineal urethrostomy

✓ perineal urethrostomy and cystorraphy via laparotomy

✓ Bladder marsupialization and cystorraphy via laparotomy

✓ Urethral fistulation

Discussion.

76

Summary & conclusion.

87

References.

91

Arabic summary.

1

List of Figures

NO.	TITLE	PAGE
1	Diagram of the urethral diverticulum (Tibary and Van Metre, 2009)	12
2	Showing penile exposure and ligation	26
3	Showing perineal urethrostomy	27
4	Showing a Foley catheter	28
5	Showing tube cystotomy in goats	29
6	Showing bladder marsupialization in goat	31
7	B7v veterinary multipurpose ultrasound scanner	33
8	Showing Examination positions in the right side for longitudinal imaging of the right kidney	34
9	Showing Examination positions in the right side for longitudinal imaging of the left kidney	34
10	Showing Examination positions at the right inguinal region	34
11	Showing digital rectal examination and perineal visualization for detection of urethral pulsation or dilatation in a calf	38
12	Showing exteriorized glans penis and urethral process amputation using scissors in a buck.	38
13	Showing perineal urethrostomy in a calf	40
14	Showing stones and urethral tissues isolated during surgery.	41
15	Showing perineal urethrostomy and cystorraphy via laparotomy in a calf	42
16	Showing Bladder marsupialization and cystorraphy via laparotomy in a calf	43
17	Showing urethral dilatation (ectazia) in a two months old buck before (A). Following urethral fistulation.	45
18	Showing urethral dilatation (ectazia) with urethral rupture in 2 weeks old calf	45
19	Showing urethral dilatation (ectazia) in 8 months old calf	45
20	Showing ultrasonogram deflated urinary bladder 48 hours after tube cystotomy using linear array probe Transabdominally at (4 MHZ).	48
21	Showing ultrasonogram a Catheter(A) and Catheter balloon (B) hours after tube cystotomy using linear array probe transabdominally at (4 MHZ).	48
22	Showing ultrasonogram of a deflated urinary bladder 48 hours after tube cystotomy using linear array probe transabdominally at (4 MHZ).	49

23	A histogram showing creatinine, urea, uric acid and serum urea nitrogen levels at different times pre-and post surgical intervention.	53
24	A histogram showing Albumin, globulin, total protein and albumin/globulin ration levels at different times pre-and post surgical intervention,	55
25	A histogram showing RBCs, WBCs, Hb and PCV levels at different times pre-and post surgical intervention.	58
26	Showing ultrasonogram of a longitudinal section through the right kidney.	61
27	Showing ultrasonogram of a transverse section through the left kidney.	61
28	Showing ultrasonogram of a longitudinal section through the left kidney using linear array endorectal probe transrectally at (4 MHZ).	61
29	Showing ultrasonogram of a normal animal showing a partially distended urinary bladder filled with an echoic fluid with regular hyperechoic walls using convex array general purpose probe trans abdominally at (4 MHZ).	61
30	Ultrasonogram in a buck 24 hours after urethral ligation showing a distended urinary bladder filled with an echoic fluid with 2 borders of the bladder wall appear only using linear array endorectal probe trans rectally at (4 MHZ).	62
31	Ultrasonogram of a buck 24 hours after urethral ligation showing a distended urinary bladder filled with an echoic fluid. 2 borders of the bladder wall appeared only using linear array endorectal probe transrectally at (4 MHZ).	62
32	Showing ultrasonogram of a distended urinary bladder filled with an echoic fluid. Urethra in the region of the internal urethral orifice in a buck 36 hours post urethral ligation using linear array endorectal probe trans rectally (4 MHZ).	62
33	Showing ultrasonogram a distended urinary bladder filled with an echoic fluid with regular hyperechoic walls in a buck 36 hours post urethral ligation using convex array general purpose probe trans abdominally at (4 MHZ).	62
34	Showing ultrasonogram in a buck 48 hours after urethral ligation showing a distended urinary bladder filled with an echoic fluid with 2 borders of the bladder wall appear only. using linear array endorectal probe trans rectally at (3.2MHZ).	62