Ain-Shams University-Faculty of Medicine
Department of Anesthesia, Intensive care and Pain Management

Airway Management in Cervical Spine Problems

An essay

Submitted for Partial Fulfillment of Master Degree in Anesthesia

Presented by

Mary Adel Awadallah

MB BCh (Menufia University)

Supervised by

Prof. Dr. Ahmed Ibrahim Ibrahim

Professor of Anesthesia, Intensive Care and Pain Management
Faculty of Medicine, Ain-Shams University

Prof. Dr. Ahmed Nagah Elshaer

Professor of Anesthesia, Intensive Care and Pain Management
Faculty of Medicine, Ain-Shams University

Dr. Hany Maher Salib

Lecturer of Anesthesia, Intensive Care and Pain Management
Faculty of Medicine, Ain-Shams University

Faculty of Medicine
Ain-Shams University
2015

Acknowledgement

Words cannot adequately express my gratitude to those who helped me to complete this work.
*First of all, I thank **GOD**, the Most Kind and Merciful for helping me to accomplish this work.*

I gratefully acknowledge the sincere advice and guidance of **Prof. Dr. Ahmed Ibrahim Ibrahim,** *Professor of Anesthesia, Intensive Care and Pain Management. Faculty of Medicine, Ain-Shams University for his constructive guidance, encouragement and valua6le help in accomplishing this work.*

I am greatly honored to express my deep appreciation to **Prof. Dr. Ahmed Nagah Elshaer,** *Professor of Anesthesia, Intensive Care and Pain Management, Faculty of Medicine, Ain-Shams University for her continuous support, sincere supervision, and direction.*

I am really thankful to **Dr. Hany Maher Salib,** *Lecturer of Anesthesia, Intensive Care and Pain Management, Faculty of Medicine, Ain-Shams University for his great help, advice, precious time, kindness, and moral support.*

Last but not least, I would like to thank my husband ***Joseph and my family*** *for their love and support.*

Mary Adel Awadallah

List of Contents

Subject *Page No.*

List of Abbreviations

Abbr.	Full-term
AFI	: Awake fiberoptic intubation
ASA	: The American Society of Anesthesiologists
AO	: Atlanto-occipital joint
BURP	: Back, Up, and Rightward Pressure
C	: Cervical
COPA	: Cuffed oro-pharyngeal airway
CICV	: Can't intubate can't ventilate
CVP	: Central venous pressure
DAS	: The Difficult Airway Society
DL	: Direct Laryngoscopy
ECG	: Electro-cardiogram
ETT	: Endotracheal tube
ETC	: Esophageal-tracheal Combitube
Fig.	: Figure
FOB	: Fiber-optic bronchoscope
GA	: General anesthesia
ILM	: Intubating laryngeal mask
IV	: Intravenous
LMA	: Laryngeal mask airway
MAIT	: manual axial in-line traction
OSA	: Obstructive sleep apnea
PCT	: Percutaneous tracheostomy
PTJV	: Percutaneous Transtracheal Jet Ventilation
RLN	: Recurrent laryngeal nerve
SGA	: Supra-Glottic Airway
SAD	: Supra Glottic Airway Device
TTJV	: Transtracheal jet ventilation
TM	: Thyromental distance.

List of Figures

List of Figures *(Cont.)*

List of Figures *(Cont.)*

List of Figures *(Cont.)*

Introduction

In patients with cervical spine problems interfering with neck mobility who will have surgery, the main concern is managing their airway. Most airway maneuvers are associated with movement of the cervical spine. Regardless of the maneuver chosen; the clinician must stabilize the cervical spine in order to minimize head and neck movement in any patient with a possible cervical spine injury. Failure to do so is associated with a 7 to 10 fold increase in neurologic injury among patients with cervical spine trauma ***(Kathleen, 2013).***

In patients with scoliosis and rheumatoid arthritis the problem in managing the airway is stiffness of the cervical spine and narrowing of the distance from the posterior arch of the atlas to the occiput which termed the atlanto-occipital gap, and a narrow atlanto-occipital gap has been cited as being a cause of difficult intubation because adequate flexion/extension movement at the atlanto-occipital joint is an essential requirement of airway management ***(Edward, 2007).***

Sometimes, there may be a compression of the airway by tumors which also interfere with airway management.

So, there are three main problems interfere with airway management:

1. Difficult direct laryngoscopy.
2. Post-operative airway obstruction.
3. Spinal cord damage ***(Ian, 2011 a).***

Airway management in such patients presents an anesthetic challenge and for decades, clinicians have debated the safest technique and device for securing the airways of these patients. Clinicians have usually focused on the association between a particular airway management technique and the degree of neck movement at a given cervical spine location. A cinefluroscopic study of posterior destabilized third cervical vertebrae in human cadavers done at University of Queensland by Joseph Brimacombe and colleagues in 2000. The investigators tried six airway management techniques when manual in line stabilization was applied. They compared face mask ventilation, direct laryngoscopic orotracheal intubation, nasal intubation, flexible fiberoptic, use of intubating laryngeal mask in conjunction with flexible fiberoscope guided tracheal intubation, use of combitube, and laryngeal airway mask insertion. The investigators concluded that the safest method of airway management based on movement criteria was the flexible fiberoptic technique ***(Basem and John, 2012), (Joseph et al., 2000).***

So in this study, different techniques used in airway management will be discussed in an attempt to reach the safest method for airway management in patients with cervical spine problems interfering with neck mobility and airway.

Anatomy of the Airway

Knowledge of anatomy is essential to the study of airway management. First, anatomical considerations are helpful in diagnosing certain problems, such as neck stabilizing problems associated with cervical spine. Second, since some procedures involved in establishing and maintaining an airway are performed under emergency conditions, little if any time may be available for reviewing anatomy. Third, in many procedures involving the airway, such as tracheal intubation, anatomical structures are only partially visible. As a result, one must recognize not only the structures in the view but also their special relationship to the surrounding structures.

The upper airway

1. The nose and nasal cavity:

Anatomically, each side of the nose consists of a floor, a roof, and medial and lateral walls. The septum forms the medial wall of each nostril and is made up of perpendicular plates of ethmoid and vomer bones and the septal cartilage. The bony plate forming the superior aspect of the septum is very thin and descends from the cribriform plate of the ethmoid bone. The lateral walls have a bony framework attached to which are three bony projections referred to as conchae or turbinates.

The upper and middle conchae are derived from the medial aspect of the ethmoid; the inferior concha is a separate structure; Figure (1) ***(Harold and Andrew, 2014).***

Nasal endotracheal tubes and nasal airways should be well lubricated, and vasoconstricting solutions should be applied to the nasal mucosa before instrumentation. When introducing a nasal endotracheal tube into the nostril, the bevel of the tube should be parallel to the nasal septum to avoid disruption of the conchae ***(Brendan et al., 2011a).***

Nerve supply

The nose is armed with a complex nervous system that includes sensory, parasympathetic, and sympathetic nerves. The sensory innervation to the olfactory mucosa is supplied by the olfactory nerve and the ophthalmic nerve through the ethmoidal nerve and trigeminal nerve through maxillary branches ***(Seema et al., 2006).***

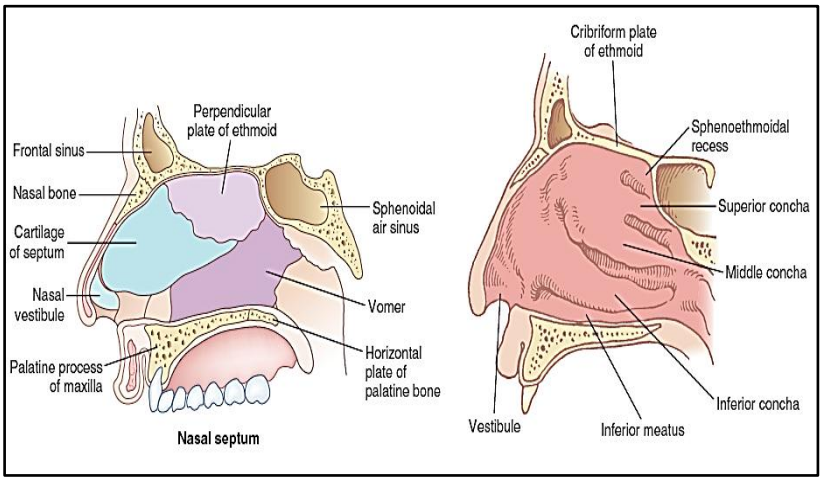

Figure (1): Sagittal section of the nose and nasal cavity ***(Lee et al., 2013)***

2. The mouth and oral cavity:

The mouth or oral cavity is divided into two parts: the vestibule and the oral cavity proper. The vestibule is the space between the lips and the cheeks externally and the gums and teeth internally. The oral cavity proper is bounded anterolaterally by the alveolar arch, teeth, and gums; superiorly by the hard and soft palates; and inferiorly by the tongue. Posteriorly, the oral cavity communicates with the palatal arches and pharynx; Figure (2) ***(John, 2011).***

Uvula in the posterior aspect of the mouth is a useful landmark for practitioners assessing the ease or difficulty of mask ventilation or tracheal intubation; Figure (2).

The tongue is an important anatomical consideration in airway management. Its size in relation to the oropharyngeal space is an important determinant of the ease or difficulty of tracheal intubation; Figure (2).

The muscles of the tongue, with the exception of palatoglossus, are supplied by the hypoglossal nerve. Palatoglossus is supplied via the pharyngeal plexus. The nerve of general sensation to the anterior two-thirds is the lingual nerve, which also carries taste sensation derived from the chorda tympani branch of the facial nerve. The nerve supplying both general and taste sensation to the posterior one-third is the glossopharyngeal nerve ***(Susan, 2008 a).***

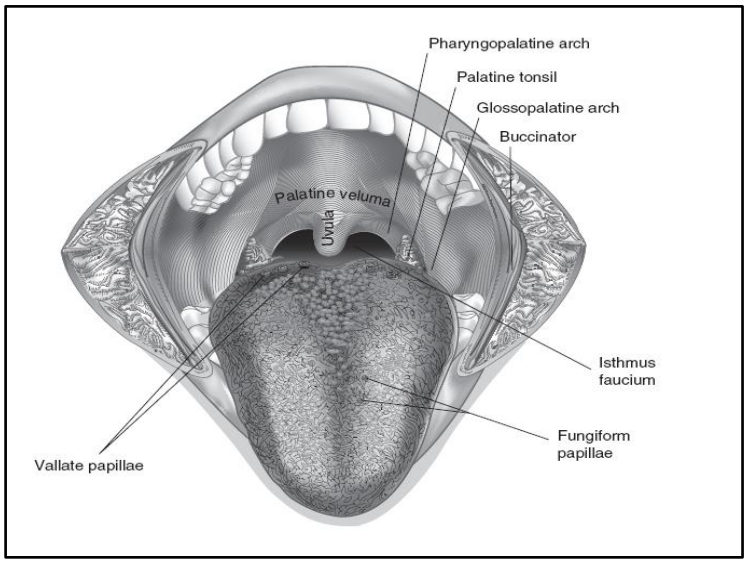

Figure (2): Oral cavity ***(John, 2011)***

3. <u>The pharynx:</u>

The pharynx is a fibromuscular tube that is semicircular in cross section and is situated directly anterior to the vertebral column. It extends from the skull base to the lower border of the cricoid cartilage at the origin of the esophagus at the level of the 6th cervical vertebra (C6). Posteriorly, it rests against the cervical vertebrae and the prevertebral fascia.

There are six muscles for the voluntary actions of the pharynx: three pharyngeal constrictor muscles that are roughly circularly layered on top of one another and three vertically oriented muscles (stylopharyngeus, salpingopharyngeus, and palatopharyngeus). These muscles aid in the act of swallowing.

The pharynx is providing a route from the oral cavity proper to the esophagus. In addition, the pharynx communicates with the nasal cavity, the middle ear cavity, and the larynx. Based on the location, the interior of the pharynx is often separated into three sections: the nasopharynx, oropharynx, and laryngopharynx; Figure (3) ***(Arjun, 2013).***

a. The nasopharynx

The nasopharynx lies behind the nasal cavity and above the soft palate. It communicates with the oropharynx through the pharyngeal isthmus, which becomes closed off during the act of swallowing.

On the lateral wall of the nasopharynx, 1 cm behind and just below the inferior nasal concha, lies the pharyngeal opening of the pharyngotympanic (Eustachian) tube. The underlying cartilage of the tube produces a bulge immediately behind its opening, termed the tubal elevation, and behind this, in turn, is a small depression which is the pharyngeal recess (fossa of Rosenmüller).

b. The oropharynx

The mouth cavity leads into the oropharynx through the oropharyngeal isthmus, which is bounded by the palatoglossal arches, the soft palate and the dorsum of the tongue. The oropharynx itself extends in height from the soft palate to the tip of the epiglottis ***(Katherine, 2008).***