

1ST CARPOMETACARPAL OSTEOARTHRITIS

Essay

Submitted for fulfillment of the master degree
in Orthopaedics

By

Ahmed Abd El Hameed El Bargisy

M.B.B.Ch.

UNDER SUPERVISION OF

Prof. Dr. Sherif Mamdouh Amr

Professor of Orthopaedics

Faculty of Medicine, Cairo University

Dr. Mostafa Mahmoud

Lecturer of Orthopaedics

Faculty of Medicine, Cairo University

Faculty of Medicine

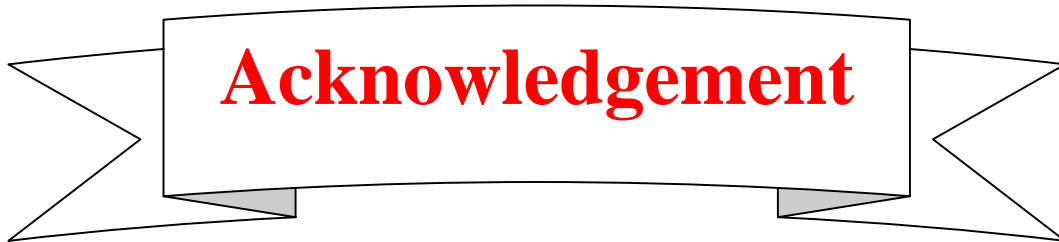
Cairo University

2010

بِسْمِ اللّٰهِ الرَّحْمٰنِ الرَّحِیْمِ



صدق الله العظيم
سورة طه اية 114



Acknowledgement

First , thanks are all to **ALLAH** for blessing this work until it has reached its end, as a part of his generous helping throughout my life.

I would like to express my sincere gratitude to professor doctor **Sherif Mamdouh Amr** professor of orthopaedics, Cairo university; for his fatherly guidance and giving me honor to work under supervision.

I would like to express my sincere gratitude to doctor **Mostafa Mahmoud** Lecturer of Orthopaedics, Cairo University; for his great support and continuous encouragement throughout this work.

My gratitude can't be fulfilled without expressing my deepest gratitude to my **parents, wife, and my son (Omar)** for their continuous support.

Abstract

The carp metacarpal joint of the thumb is a distinguishing, yet notorious feature of the human opposable thumb. On the one hand, it is fittingly also known as the basal joint, since it is the “base” from which the thumb has a large range of motion, and therefore, permits the hand to perform many functions. On the other hand, its unique anatomic configuration, which allows this vital motion, also predisposes the basal joint to degeneration and arthritis.

Key word: OSTEOARTHRITIS. Orthopedics. CMC

List of figures

Figure 1	The left Trapezium
Figure 2	Palmar (A) and dorsal (B) views of the right thumb showing the ligamentous support of the carpometacarpal (CMC) joint.
Figure3	Photographs of cadaveric specimen show trapeziometacarpal joint.
Figure 4	The trapeziometacarpal joint.
Figure 5	MR arthrography of cadaveric specimen.
Figure 6	Photograph of surgically dissected cadaveric specimen, Sagittal MR arthrography image, and photograph of anatomic section of trapeziometacarpal joint.
Figure7	Sagittal T1-weighted MR images of cadaveric specimen before (A) and after (B) arthrography.
Figure8	Trapezio-metacarpal osteoarthritis outcome.
Figure 9	Palpation of the volar aspect of the thumb CMCJ elicits pain in patients with joint degeneration.
Figure10	Grind test for carpometacarpal osteoarthritis.
Figure 11	(A–C) Three radiograph views of a patient with Eaton stage 2 CMCJ disease.
Figure 12	A “stress” radiograph of the thumbs.

Figure 13	(A) Clinical photograph demonstrating the position of the hand to evaluate the CMCJ using the Roberts view. (B) Radiograph of the Roberts view with Eaton stage 1 CMCJ disease.
Figure 14	Kapandji views.
Figure 15	Trapezial slope assessment.
Figure 16	Ultrasonography in early cases.
Figure 17	MR image shows fragment of torn deep anterior oblique ligament.
Figure 18	Rhizarthrosis with extensive bone edema.
Figure 19	Examples of 1CMC dGEMRIC acquired 60 min after injection.
Figure 20	Examples of adaptive equipments for CMC OA.
Figure 21	(a, b) Orthogonal views of a custom molded long thumb splint.
Figure 22	(a, b) Orthogonal views of a custom molded short thumb splint with the thumb IP joint left free.
Figure 23	TMJ injection technique, illustrating the TM joint line and the course of the abductor pollicis longus tendon.
Figure24	A, Preparation for the osteotomy of metacarpal metaphysis.
Figure 25	B, Dorsoradial metacarpal osteotomy performed.

Figure 26	C, Closure of the metacarpal osteotomy.
Figure 27	A, Retrograde fixation of the metacarpal osteotomy by Kirschner wire.
Figure 28	B, Centralizing Kirschner wire fixation of the metacarpal osteotomy.
Figure 29	A, Preoperative radiograph showing subluxation of the metacarpal.
Figure 30	B, Postoperative radiograph showing well reduced joint surfaces fixed with a Kirschner wire.
Figure 31	C, Healed osteotomy of the metacarpal after Kirschner wire removal.
Figure 32	Volar beak ligament reconstruction.
Figure 33	The costochondral allograft is carved with a scalpel to match the shape of the space between the distal surface of the trapezium and the base of the thumb metacarpal.
Figure 34	The strip of the FCR is threaded through the trapezium, the carved allograft cartilage, and the base of the thumb metacarpal (MCI).
Figure 35	Tendon interposition arthroplasty with ligament reconstruction.
Figure 36	Kleinman and Eckenrode technique for Ligament reconstruction and tendon interposition.
Figure 37	Kriegs et al. technique of ligament reconstruction.

	Skin incision.
Figure38	Kriegs et al. technique of ligament reconstruction. Surgical approach to the trapeziometacarpal joint.
Figure 39	Kriegs et al. technique of ligament reconstruction. Preparation of the flexor carpi radialis (FCR) tendon in the depths of the arthroplasty space.
Figure40	Kriegs et al. technique of ligament reconstruction. Incision of the flexor carpi radialis (FCR) tendon proximal to the suture.
Figure41	Kriegs et al. technique of ligament reconstruction. The incision in the midportion of the flexor carpi radialis (FCR) tendon courses distally.
Figure42	Kriegs et al. technique of ligament reconstruction. A 4.0 Vicryl suture is placed to secure the tendon strip of the flexor carpi radialis (FCR) in the depths of the arthroplasty space.
Figure 43	Kriegs et al. technique of ligament reconstruction. Creation of the 3.2-mm drill canal in the base of the first metacarpal.
Figure44	Kriegs et al. technique of ligament reconstruction. A wire snare is used to grasp the free end of the Vicryl suture, thereby routing it slowly back through the canal.
Figure45	Kriegs et al. technique of ligament reconstruction. Suture fixation of the protruding remainder of the strip of the flexor carpi radialis tendon to the base

	of the first metacarpal.
Figure 46	Thomson suspensionplasty.
Figure 47	Hyperextension of the MCP in this patient resulting in difficulties in performing the thumb-index terminolateral pinch.
Figure 48	Results after 10 years of follow-up of a trapeziectomy and ligament reconstruction with a half FCR.
Figure 49	Plate and screw fixation of TM joint.
Figure 50	Fused TM joint.
Figure 51	Marti technique of trapezio-metacarpal arthrodesis.
Figure 52	Arthrodesis with three K-wires.
Figure 53	Methods of carpometacarpal arthrodesis.
Figure54	Arthrodesis of carpometacarpal joint of thumb for osteoarthritis using square bone peg for internal fixation.
Figure55	Sliding bone graft technique for arthrodesis of the trapeziometacarpal joint of the thumb.
Figure56	Ashworth technique for Resurfacing arthroplasty.
Figure57	Hirata et al. technique of combined use of ligament reconstruction with surface replacement arthroplasty. Skin incisions.
Figure58	Hirata et al. technique of combined use of

	ligament reconstruction with surface replacement arthroplasty. Joint resurfacing.
Figure 59	A-C, Swanson et al. technique for convex condylar arthroplasty.
Figure 60	Method of reinforcing thumb carpometacarpal capsule during implant arthroplasty.
Figure 61	Method for inserting Eaton trapezoidal prosthesis.
Figure 62	Radiograph of implanted de la Caffinier's prosthesis.
Figure 63	The Steffee metacarpophalangeal joint implant.
Figure 64	second-generation GUEPAR prosthesis in four sizes for the metacarpal with two neck lengths and a single trapezoidal cup size.
Figure 65	Badia et al. technique for total joint replacement arthroplasty First, the polyethylene cup is cemented in the trapezium.
Figure 66	Badia et al. technique for total joint replacement arthroplasty Cementing and placement of the metacarpal stem in the medullary canal.
Figure 67	Badia et al. technique for total joint replacement arthroplasty Reduction of both components is followed by testing for stability and impingement of the prosthesis.
Figure 68	Badia et al. technique for total joint replacement arthroplasty Fluoroscopic views are obtained to

	assess proper cementing and correct implant positioning.
Figure 69	asic initial first CMC set-up, utilizing the 1-R portal for the 1.9-mm arthroscope and the 1-U portal for the “working portal.”
Figure 70	Arthroscopic view of a 2.9-mm burr used to remove a loose body (LB).
Figure 71	Shrinkage capsulorrhaphy.
Figure72	Fluoroscopic image of the resected trapezium stabilized with a K-wire.
Figure 73	Suggested protocol for management of trapezio-metacarpal arthritis, considering arthroscopic findings and including recommended treatment.
Figure74	Arthroscopic Stage I findings demonstrate synovitis around the volar oblique ligament, with intact articular cartilage on the trapezium.
Figure75	Arthroscopic Stage II typical findings include small area of articular cartilage loss on deep aspect of metacarpal at insertion of volar beak ligament and central, focal loss of trapezium joint surface.
Figure 76	Arthroscopic Stage III findings include diffuse articular cartilage loss on both trapezium and metacarpal base.

Figure 77	The approaches used in Durand et al. study of neurovascular relationships of the approaches used during arthroscopic total trapeziectomy with the Thompson “suspension-plasty”.
Figure78	The relationship between the arthroscopic portals and three main branches of the SBRN.
Figure 79	Neurovascular relationships of the ulnar approach.
Figure 80	Study of the neurovascular relationships of the radial approach.
Figure 81	Neurovascular relationships of the “trans-M1” approach.
Figure82	Specimen demonstrating the implantation sites of three main portals.

List of tables

Table 1	Ligaments Stabilizing the Trapezium and Trapeziometacarpal Joint.
Table 2	Major ligaments of the trapeziometacarpal joint.
Table 3	Dell's radiologic classification for peritrapezial osteoarthritis.
Table 4	Burton classification system for trapeziometacarpal arthritis.
Table 5	Staging of osteoarthritis of the first carpometacarpal joint, as described by Eaton and Glickel.
Table 6	Badia's Arthroscopic Classification.
Table 7	The management outline based on Saunders and Beatus et al.

List of Abbreviations

1-R	First Radial (Wrist arthroscopic Approach)
1-U	First ulnar (Wrist arthroscopic Approach)
AA	adductor aponeurosis
AOL	anterior oblique ligament
APB	abductor pollicis brevis
APL	abductor pollicis longus
APL	abductor pollicis longus
CMC	Carpometacarpal
CMC1	First Carpometacarpal
dAOL	deep anterior oblique ligament
DASH score	Disabilities of the Arm, Shoulder and Hand score
dGEMRIC	Delayed gadolinium enhanced MRI of cartilage
DIML	dorsal intermetacarpal
DRL	dorsoradial ligament
DT-II MC	dorsal trapezio-second metacarpal
DTT	dorsal trapeziotrapezoid
EPB	extensor pollicis brevis
EPL	extensor pollicis longus

List of Abbreviations

FCR	flexor carpi radialis
FPL	flexor pollicis longus
IM	Intermetacarpal
JP	Joint protection
JSN	joint space narrowing
K-wire	Kirschner wire
LB	Loose body
LCNF	lateral cutaneous nerve of the forearm
LRTI	ligament reconstruction and tendon interposition
MCP-rad	Metacarpophalangeal-radial (Arthroscopic Approach)
MCP-uln	Metacarpophalangeal-ulnar (Arthroscopic Approach)
NSAIDs	Non-steroidal anti-inflammatory drugs
OA	Osteoarthritis
PA	Postero-anterior
PL	palmaris longus
POL	posterior oblique ligament
PPT	Purdue pegboard test
RA	radial artery
ROM	Range of motion