



ROLE OF MRI IN ASSESSMENT OF NODULAR FOCAL LESIONS IN CIRRHOTIC LIVER

Thesis

Submitted for Partial Fulfillment of M.Sc.
In Radiodiagnosis

By

Ahmed Riyadh Abdulameer
(M.B;B.Ch.)

Supervised by

Dr. Samer Malak Botros
Assistant Professor of Radiodiagnosis
Faculty of Medicine - Ain Shams University

Dr. Mennatallah Hatem Shalaby

Lecturer of Radiodiagnosis
Faculty of Medicine - Ain shams University

Faculty of Medicine
Ain Shams University
2017

List of Contents

Title	Page
▪ List of Abbreviations	I
▪ List of Tables	II
▪ List of Figures	IV
▪ Abstract	VII
▪ Introduction	1
▪ Aim of the Work	4
▪ Review of Literature	
- Gross Anatomy.....	5
- Pathology of liver cirrhosis and associated nodules.....	20
- Technique of MR examination of the liver	60
▪ Patients and Methods	75
▪ Results	82
▪ Case Presentation	90
▪ Discussion	112
▪ Summary	119
▪ Conclusions	121
▪ References	122
▪ Arabic Summary	--

List of Abbreviations

3D	Three Dimension
BLC	Barcelona Clinic Liver Cancer
CMV	Cytomegalovirus
CT	Computed Tomography
CUPI	Construction of the Chinese University Prognostic Index
Gd-DTPA	Gadolinium Diethylenetriamine penta-acetic acid
GFR	Glomerular Filtration Rate
GRE	Gradient Echo Sequence
HCC	Hepatocellular Carcinoma
LI-RADS	Liver Imaging - Reporting and Data System
MRI	Magnetic Resonance Imaging
RARE	Rapid Acquisition with Relaxation Enhancement
SPIO	Super Paramagnetic Iron Oxide
TE	Time Echo
TR	Time Repetition
U/S	Ultrasonography

List of Tables

Table No.	Title	Page
Table (1):	Segments numbering of the liver	8
Table (2):	Pathological classification of hepatic focal lesion	20
Table (3):	The Child-Pugh classification is a means of assessing the severity of liver cirrhosis	22
Table (4):	Risk factors of HCC	26
Table (5):	Recommendations for HCC surveillance: categories of adult patients in whom surveillance is recommended.....	28
Table (6):	Typical morphologic changes of liver cirrhosis.....	36
Table (7):	Shows that the male (65%) and female (35%) of sex.....	82
Table (8):	Site of the pathological lesions distribution of the study group	82
Table (9):	Accuracy of MR findings	83
Table (10):	Number and Percentage of different histopathological diagnosis in our study	83
Table (11):	Number and Percentage of different MRI diagnosis	83
Table (12):	T1 signal intensity distribution of the study group.....	84

Table (13): T2 signal intensity distribution on T2
WI..... 85

Table (14): Variable T1 WI signal intensities of
different MRI lesions 87

Table (15): Variable T2 WI signal intensities of
different MRI lesions 88

Table (16): Different enhancement patterns of
MRI lesions 89

List of Figures

Figure No.	Title	Page
Fig. (1):	Gross right and left anatomical lobes of the liver based on falciform ligament.....	6
Fig. (2):	Gross anatomical lobes of the liver	7
Fig. (3):	Liver segmental anatomy according to Couinaud classification	9
Fig. (4):	Ligaments of the liver	10
Fig. (5):	Simplified scheme of the liver segments in relation to the portal vein branches.....	11
Fig. (6):	Normal anatomy of the celiac Artery	11
Fig. (7):	Arrangement of the hepatic venous territories	12
Fig. (8):	Anatomy of the biliary system	13
Fig. (9):	Normal hepatic veins.....	14
Fig. (10):	Portal vein anatomy	15
Fig. (11):	Sagittal MR images of the liver	16
Fig. (12):	Coronal MR images of the liver	17
Fig. (13):	Normal MR Liver signal intensity on T1-weighted non contrast axial image	18

Fig. (14):	Normal MR Liver signal intensity on T2-weighted non contrast axial image	19
Fig. (15):	Macroscopic view showing a homogeneous encapsulated HCC without necrosis or hemorrhage	27
Fig. (16):	Stepwise pathway of carcinogenesis for HCC in cirrhosis	30
Fig. (17):	Diagnostic algorithm and recall policy for a mass/nodule in cirrhotic or non cirrhotic livers	31
Fig. (18):	Updated BCLC staging system and treatment strategy	32
Fig. (19):	T2-weighted TSE image in early cirrhosis shows enlargement of the hilarperiportal space between the left medial segment and the right portal vein	36
Fig. (20):	T1-weighted gradient-echo (GRE) in-phase (TE,4.7 ms) image in advanced cirrhosis	37
Fig. (21):	Innumerable regenerative nodules	38
Fig. (22):	Hepatic parenchymal alterations at unenhanced MR imaging in a man with HCV-related cirrhosis	39
Fig. (23):	Steatotic regenerative nodules with cirrhosis secondary to fatty liver disease	40

Fig. (24):	Regenerative siderotic nodules	41
Fig. (25):	Low-grade and high-grade dysplastic nodules	43
Fig. (26):	Dynamic enhancement patterns of a high-grade dysplastic nodule.....	44
Fig. (27):	Nodule-within-a-nodule abnormality ...	45
Fig. (28):	Large solitary HCC	48
Fig. (29):	HCC with capsule.....	50
Fig. (30):	Hypovascular HCC with fat	52
Fig. (31):	HCC extending into IVC	54
Fig. (32):	Typical hepatocellular carcinoma	55
Fig. (33):	LI-RADS.....	59
Fig. (34):	Axial breath-hold in-phase	65

Abstract

Cirrhotic livers are characterized by the formation of hepatocellular nodules which are classified histologically as either (regenerative nodules, dysplastic or neoplastic lesions). Differential diagnosis is important, and it is facilitated by comparing the clinical and pathological findings with radiological imaging features. Familiarity with the MR imaging characteristics of cirrhosis-associated hepatocellular nodules is therefore important for optimal diagnosis and management of cirrhotic disease.

Key words:

MRI- magnetic resonance imaging

HCC- Hepatocellular carcinoma

INTRODUCTION

Liver cirrhosis is the end stage of a wide variety of hepatic disease processes that cause hepatocellular inflammation and necrosis leading to hepatic fibrosis and nodular regeneration. The common causes of the liver cirrhosis is: viral hepatitis C (55%), viral hepatitis B ((16%)), Alcoholic patient (13%), and there is less common causes: cryptogenic nonalcoholic fatty liver disease and nonalcoholic steatohepatitis (16%). Nonalcoholic steatohepatitis is known to be an advanced stage of nonalcoholic fatty liver disease (*Adam et al., 2014*).

Cirrhosis-associated hepatocellular nodules form due to local proliferation of the hepatocytes and their stroma as a result of liver injury lead to the formation of this regeneration nodules. The regenerative nodules formation is a compensatory mechanism by the liver to replace the damaged hepatocytes and to compensate the lost liver function. In some of these regenerative nodules, some of their hepatocytes may undergo cellular changes with atypia and hence progress to liver cell dysplasia. These changes made the nodule to increase in size and cellularity leading to the formation of dysplastic nodules and as a result hepatocellular carcinoma (HCC) (*Hussain et al., 2009*).

In 1995, an International Working Party panel published guidelines for classification and description of the nodular hepatocellular lesions. These guidelines, the hepatocellular nodules divided into groups; regenerative lesions, dysplastic and neoplastic lesions.

Regenerative nodules: these either monoacinar or multiacinar and this depend if they contain one or more terminal portal tract, it also may be micronodules (<3 mm) or macronodules (≥ 3 mm). Also there is what called giant regenerative nodules which measure 5 cm in diameter, but they are rare (*Robert et al., 2008*).

Lesions with **dysplastic features** that do not have the feature of invasion or malignancy (*Bruix & Sherman et al, 2005*).

Hepatocellular Carcinoma: These are malignant neoplasms which consist of dedifferentiated hepatocytes. These can be either as small (<2 cm in diameter) or large (≥ 2 cm in diameter). The classic system of macroscopic classification of hepatocellular carcinomas in use since 1901 includes three major types; nodular, massive and diffuse (*Robert et al., 2008*).

Siderotic Nodule is an iron rich either regenerative or dysplastic nodule where differentiation between them radiologically till now is not possible (*Mandell et al., 2013*).

MR imaging can successfully help to detect the increasing size and vascularity of nodules. It also provide support for the concept of stepwise carcinogenesis (*Van Den Bos et al., 2006*).

MR imaging has emerged as an important modality for the assessment of cirrhosis-associated hepatocellular nodules because of many reasons when compare to other modalities like the U/S and CT scan such of these causes better soft-tissue contrast, assessing a larger number of tissue properties, more sensitivity to contrast media (*Bartolozzi et al., 2007*).

MRI characterization of the nodules by morphology, signal intensity on different sequences and their behavior with gadolinium. Also there is specific contrast agents, but they are not commonly used due to their high cost (*Maria et al., 2010*).

Two major causes made MR imaging as an important modality in the imaging and the assessment of cirrhosis and its complications, such as HCC. These causes: *First*, faster sequences with high quality images and high soft tissue contrast. *Second*, the use of automated contrast detection methods in combination with faster sequences allows reproducible capture of the arterial phase which is essential for the detection and characterization of HCC (*Hussain et al., 2009*).

AIM OF THE WORK

The aim of this work is to study the role of MRI in characterization of nodular focal lesions in cirrhotic liver by MRI.

GROSS ANATOMY

The liver is the largest solid organ in the body. It lies in the upper part of the abdominal cavity just beneath the diaphragm and mostly under cover of the ribs. It fills the right hypochondrium and extends across the epigastrium into the left hypochondrium (*Standring et al., 2005*).

The normal liver is shaped like a wedge with its base against the right abdominal wall, and its tip pointing to the spleen and extends from the fifth left intercostal space to the right mid clavicular line down to the right costal margin. It measures 12 to 15 cm coronally and 15 to 20 cm transversely. The median liver weight is 1800 gm in men and 1400 gm in women (*Schiff et al., 2007*).

A-Functional and Morphological Anatomy:

Liver anatomy can be described using two different aspects: morphological anatomy and functional anatomy. The classical morphological description of the liver anatomy is based on the external appearance. On the diaphragmatic surface, the falciform ligament divides the liver into the right and left anatomical lobes (Fig. 1). In this classical morphological description, the quadrate lobe belongs to the right lobe of the liver, but functionally it is part of left lobe (*Rubin et al., 2006*).

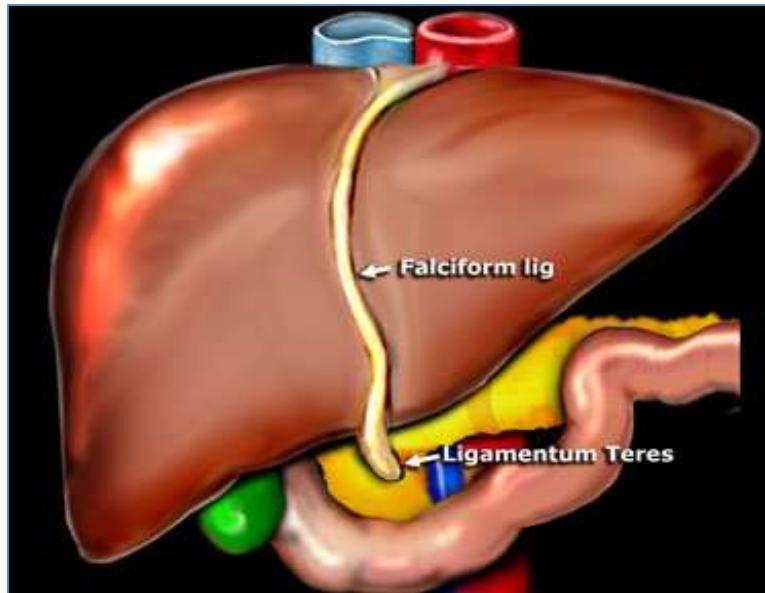


Fig. (1): Gross right and left anatomical lobes of the liver based on falciform ligament (*Quoted from Rubin et al., 2006*).

Morphological Anatomy:

Historically the gross anatomical appearance of the liver has been divided into right, left, caudate and quadrate lobes by surface peritoneal and ligamentous attachments (Fig. 2). The falciform ligament superiorly and the ligamentum venosum inferiorly, mark the division between right and left lobes. The quadrate lobe lies anteriorly, and the caudate lobe lies posteriorly. The gall bladder usually lies in a shallow fossa to the right of the quadrate lobe (*Standring et al., 2005*).