



# **ROLE OF MRI IN ASSESSMENT OF NODULAR FOCAL LESIONS IN CIRRHOTIC LIVER**

*Thesis*

Submitted for Partial Fulfillment of M.Sc.  
***In Radiodiagnosis***

*By*

**Ahmed Riyadh Abdulameer**  
(M.B;B.Ch.)

*Supervised by*

**Dr. Samer Malak Botros**  
Assistant Professor of Radiodiagnosis  
Faculty of Medicine - Ain Shams University

**Dr. Mennatallah Hatem Shalaby**

Lecturer of Radiodiagnosis  
Faculty of Medicine - Ain shams University

Faculty of Medicine  
Ain Shams University  
2017

# List of Contents

Title	Page
▪ <b>List of Abbreviations</b> .....	I
▪ <b>List of Tables</b> .....	II
▪ <b>List of Figures</b> .....	IV
▪ <b>Abstract</b> .....	VII
▪ <b>Introduction</b> .....	1
▪ <b>Aim of the Work</b> .....	4
▪ <b>Review of Literature</b>	
- Gross Anatomy.....	5
- Pathology of liver cirrhosis and associated nodules.....	20
- Technique of MR examination of the liver .....	60
▪ <b>Patients and Methods</b> .....	75
▪ <b>Results</b> .....	82
▪ <b>Case Presentation</b> .....	90
▪ <b>Discussion</b> .....	112
▪ <b>Summary</b> .....	119
▪ <b>Conclusions</b> .....	121
▪ <b>References</b> .....	122
▪ <b>Arabic Summary</b> .....	--

## List of Abbreviations

<b>3D</b> .....	Three Dimantion
<b>BLC</b> .....	Barcelona Clinic Liver Cancer
<b>CMV</b> .....	Cytomegalovirus
<b>CT</b> .....	Computed Tomography
<b>CUPI</b> .....	Construction f the chinese University prognostic Index
<b>Gd-DTPA</b> .....	Gadolinium Diethylenetriamine penta-acetic acid
<b>GFR</b> .....	Glomerular Filtration Rate
<b>GRE</b> .....	Gradient Echo Sequence
<b>HCC</b> .....	Hepatocellular Carcinoma
<b>LI-RADS</b> .....	Liver Imaging - Reporting and Data System
<b>MRI</b> .....	Magnetic Resonance Imaging
<b>RARE</b> .....	Rapid Acquisition with relaxation enhancement
<b>SPIO</b> .....	Super Paramagnetic Iron Oxide
<b>TE</b> .....	Time Echo
<b>TR</b> .....	Time Repetition
<b>U/S</b> .....	Ultrasonography

## List of Tables

Table No.	Title	Page
<b>Table (1):</b>	Segments numbering of the liver .....	8
<b>Table (2):</b>	Pathological classification of hepatic focal lesion .....	20
<b>Table (3):</b>	The Child-Pugh classification is a means of assessing the severity of liver cirrhosis .....	22
<b>Table (4):</b>	Risk factors of HCC .....	26
<b>Table (5):</b>	Recommendations for HCC surveillance: categories of adult patients in whom surveillance is recommended.....	28
<b>Table (6):</b>	Typical morphologic changes of liver cirrhosis.....	36
<b>Table (7):</b>	Shows that the male (65%) and female (35%) of sex.....	82
<b>Table (8):</b>	Site of the pathological lesions distribution of the study group .....	82
<b>Table (9):</b>	Accuracy of MR findings .....	83
<b>Table (10):</b>	Number and Percentage of different histopathological diagnosis in our study .....	83
<b>Table (11):</b>	Number and Percentage of different MRI diagnosis .....	83
<b>Table (12):</b>	T1 signal intensity distribution of the study group.....	84

**Table (13):** T2 signal intensity distribution on T2  
WI..... 85

**Table (14):** Variable T1 WI signal intensities of  
different MRI lesions ..... 87

**Table (15):** Variable T2 WI signal intensities of  
different MRI lesions ..... 88

**Table (16):** Different enhancement patterns of  
MRI lesions ..... 89

## List of Figures

Figure No.	Title	Page
<b>Fig. (1):</b>	Gross right and left anatomical lobes of the liver based on falciform ligament.....	6
<b>Fig. (2):</b>	Gross anatomical lobes of the liver .....	7
<b>Fig. (3):</b>	Liver segmental anatomy according to Couinaud classification .....	9
<b>Fig. (4):</b>	Ligaments of the liver .....	10
<b>Fig. (5):</b>	Simplified scheme of the liver segments in relation to the portal vein branches.....	11
<b>Fig. (6):</b>	Normal anatomy of the celiac Artery ....	11
<b>Fig. (7):</b>	Arrangement of the hepatic venous territories .....	12
<b>Fig. (8):</b>	Anatomy of the biliary system .....	13
<b>Fig. (9):</b>	Normal hepatic veins.....	14
<b>Fig. (10):</b>	Portal vein anatomy .....	15
<b>Fig. (11):</b>	Sagittal MR images of the liver .....	16
<b>Fig. (12):</b>	Coronal MR images of the liver .....	17
<b>Fig. (13):</b>	Normal MR Liver signal intensity on T1-weighted non contrast axial image .....	18

<b>Fig. (14):</b>	Normal MR Liver signal intensity on T2-weighted non contrast axial image .....	19
<b>Fig. (15):</b>	Macroscopic view showing a homogeneous encapsulated HCC without necrosis or hemorrhage .....	27
<b>Fig. (16):</b>	Stepwise pathway of carcinogenesis for HCC in cirrhosis .....	30
<b>Fig. (17):</b>	Diagnostic algorithm and recall policy for a mass/nodule in cirrhotic or non cirrhotic livers .....	31
<b>Fig. (18):</b>	Updated BCLC staging system and treatment strategy .....	32
<b>Fig. (19):</b>	T2-weighted TSE image in early cirrhosis shows enlargement of the hilarperiportal space between the left medial segment and the right portal vein .....	36
<b>Fig. (20):</b>	T1-weighted gradient-echo (GRE) in-phase (TE,4.7 ms) image in advanced cirrhosis .....	37
<b>Fig. (21):</b>	Innumerable regenerative nodules .....	38
<b>Fig. (22):</b>	Hepatic parenchymal alterations at unenhanced MR imaging in a man with HCV-related cirrhosis .....	39
<b>Fig. (23):</b>	Steatotic regenerative nodules with cirrhosis secondary to fatty liver disease .....	40

<b>Fig. (24):</b>	Regenerative siderotic nodules .....	41
<b>Fig. (25):</b>	Low-grade and high-grade dysplastic nodules .....	43
<b>Fig. (26):</b>	Dynamic enhancement patterns of a high-grade dysplastic nodule.....	44
<b>Fig. (27):</b>	Nodule-within-a-nodule abnormality ...	45
<b>Fig. (28):</b>	Large solitary HCC .....	48
<b>Fig. (29):</b>	HCC with capsule.....	50
<b>Fig. (30):</b>	Hypovascular HCC with fat .....	52
<b>Fig. (31):</b>	HCC extending into IVC .....	54
<b>Fig. (32):</b>	Typical hepatocellular carcinoma .....	55
<b>Fig. (33):</b>	LI-RADS.....	59
<b>Fig. (34):</b>	Axial breath-hold in-phase .....	65



## **Abstract**

Cirrhotic livers are characterized by the formation of hepatocellular nodules which are classified histologically as either (regenerative nodules, dysplastic or neoplastic lesions). Differential diagnosis is important, and it is facilitated by comparing the clinical and pathological findings with radiological imaging features. Familiarity with the MR imaging characteristics of cirrhosis-associated hepatocellular nodules is therefore important for optimal diagnosis and management of cirrhotic disease.

### **Key words:**

MRI- magnetic resonance imaging

HCC- Hepatocellular carcinoma

## INTRODUCTION

Liver cirrhosis is the end stage of a wide variety of hepatic disease processes that cause hepatocellular inflammation and necrosis leading to hepatic fibrosis and nodular regeneration. The common causes of the liver cirrhosis is: viral hepatitis C (55%), viral hepatitis B ((16%)), Alcoholic patient (13%), and there is less common causes: cryptogenic nonalcoholic fatty liver disease and nonalcoholic steatohepatitis (16%). Nonalcoholic steatohepatitis is known to be an advanced stage of nonalcoholic fatty liver disease (*Adam et al., 2014*).

Cirrhosis-associated hepatocellular nodules form due to local proliferation of the hepatocytes and their stroma as a result of liver injury lead to the formation of this regeneration nodules. The regenerative nodules formation is a compensatory mechanism by the liver to replace the damaged hepatocytes and to compensate the lost liver function. In some of these regenerative nodules, some of their hepatocytes may undergo cellular changes with atypia and hence progress to liver cell dysplasia. These changes made the nodule to increase in size and cellularity leading to the formation of dysplastic nodules and as a result hepatocellular carcinoma (HCC) (*Hussain et al., 2009*).

In 1995, an International Working Party panel published guidelines for classification and description of the nodular hepatocellular lesions. These guidelines, the hepatocellular nodules divided into groups; regenerative lesions, dysplastic and neoplastic lesions.

**Regenerative nodules:** these either monoacinar or multiacinar and this depend if they contain one or more terminal portal tract, it also may be micronodules (<3 mm) or macronodules ( $\geq 3$  mm). Also there is what called giant regenerative nodules which measure 5 cm in diameter, but they are rare (*Robert et al., 2008*).

Lesions with **dysplastic features** that do not have the feature of invasion or malignancy (*Bruix & Sherman et al, 2005*).

**Hepatocellular Carcinoma:** These are malignant neoplasms which consist of dedifferentiated hepatocytes. These can be either as small (<2 cm in diameter) or large ( $\geq 2$  cm in diameter). The classic system of macroscopic classification of hepatocellular carcinomas in use since 1901 includes three major types; nodular, massive and diffuse (*Robert et al., 2008*).

**Siderotic Nodule** is an iron rich either regenerative or dysplastic nodule where differentiation between them radiologically till now is not possible (*Mandell et al., 2013*).

MR imaging can successfully help to detect the increasing size and vascularity of nodules. It also provide support for the concept of stepwise carcinogenesis (*Van Den Bos et al., 2006*).

MR imaging has emerged as an important modality for the assessment of cirrhosis-associated hepatocellular nodules because of many reasons when compare to other modalities like the U/S and CT scan such of these causes better soft-tissue contrast, assessing a larger number of tissue properties, more sensitivity to contrast media (*Bartolozzi et al., 2007*).

MRI characterization of the nodules by morphology, signal intensity on different sequences and their behavior with gadolinium. Also there is specific contrast agents, but they are not commonly used due to their high cost (*Maria et al., 2010*).

Two major causes made MR imaging as an important modality in the imaging and the assessment of cirrhosis and its complications, such as HCC. These causes: *First*, faster sequences with high quality images and high soft tissue contrast. *Second*, the use of automated contrast detection methods in combination with faster sequences allows reproducible capture of the arterial phase which is essential for the detection and characterization of HCC (*Hussain et al., 2009*).

## **AIM OF THE WORK**

The aim of this work is to study the role of MRI in characterization of nodular focal lesions in cirrhotic liver by MRI.

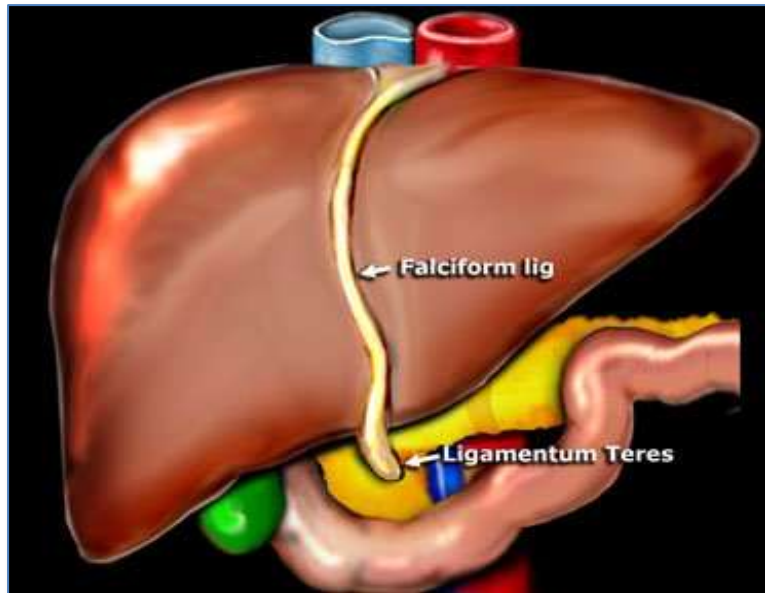
## GROSS ANATOMY

The liver is the largest solid organ in the body. It lies in the upper part of the abdominal cavity just beneath the diaphragm and mostly under cover of the ribs. It fills the right hypochondrium and extends across the epigastrium into the left hypochondrium (*Standring et al., 2005*).

The normal liver is shaped like a wedge with its base against the right abdominal wall, and its tip pointing to the spleen and extends from the fifth left intercostal space to the right mid clavicular line down to the right costal margin. It measures 12 to 15 cm coronally and 15 to 20 cm transversely. The median liver weight is 1800 gm in men and 1400 gm in women (*Schiff et al., 2007*).

### A-Functional and Morphological Anatomy:

Liver anatomy can be described using two different aspects: morphological anatomy and functional anatomy. The classical morphological description of the liver anatomy is based on the external appearance. On the diaphragmatic surface, the falciform ligament divides the liver into the right and left anatomical lobes (Fig. 1). In this classical morphological description, the quadrate lobe belongs to the right lobe of the liver, but functionally it is part of left lobe (*Rubin et al., 2006*).



**Fig. (1):** Gross right and left anatomical lobes of the liver based on falciform ligament (*Quoted from Rubin et al., 2006*).

### ***Morphological Anatomy:***

Historically the gross anatomical appearance of the liver has been divided into right, left, caudate and quadrate lobes by surface peritoneal and ligamentous attachments (Fig. 2). The falciform ligament superiorly and the ligamentum venosum inferiorly, mark the division between right and left lobes. The quadrate lobe lies anteriorly, and the caudate lobe lies posteriorly. The gall bladder usually lies in a shallow fossa to the right of the quadrate lobe (*Standring et al., 2005*).