شبكة المعلومات الجامعية

التوثيق الإلكتروني والميكروفيلم

بسم الله الرحمن الرحيم

HANAA ALY

شبكة المعلومات الجامعية

التوثيق الالكتروني والميكروفيلم

HANAA ALY

شبكة المعلومات الجامعية

التوثيق الإلكتروني والميكروفيلم

جامعة عين شمس

التوثيق الإلكتروني والميكروفيلم

قسم

نقسم بالله العظيم أن المادة التي تم توثيقها وتسجيلها
علي هذه الأقراص المدمجة قد أعدت دون أية تغيرات

يجب أن

تحفظ هذه الأقراص المدمجة بعيدا عن الغبار

HANAA ALY

Comparing the Diagnostic Efficacy of Digital Breast Tomosynthesis with Full Field Digital Mammography Using BI-RADS Scoring.

A Thesis

Submitted for the Partial Fulfilment of the Requirements of the Doctorate Degree in Radiology

Presented by

Rana Mamdouh Naeim Tolba
M.B., B. Ch., M. Sc
Faculty of Medicine - Ain Shams University

Under supervision of

Prof. Dr. Rania Aly Marouf
Professor of Radiology
Faculty of Medicine - Ain Shams University

Dr. Merhan Ahmed Nasr
Lecturer of Radiology
Faculty of Medicine - Ain Shams University

Dr. Marwa El Sayed Abd El-Rahman
Lecturer of Radiology
Faculty of Medicine - Ain Shams University

Faculty of Medicine Ain Shams University 2021

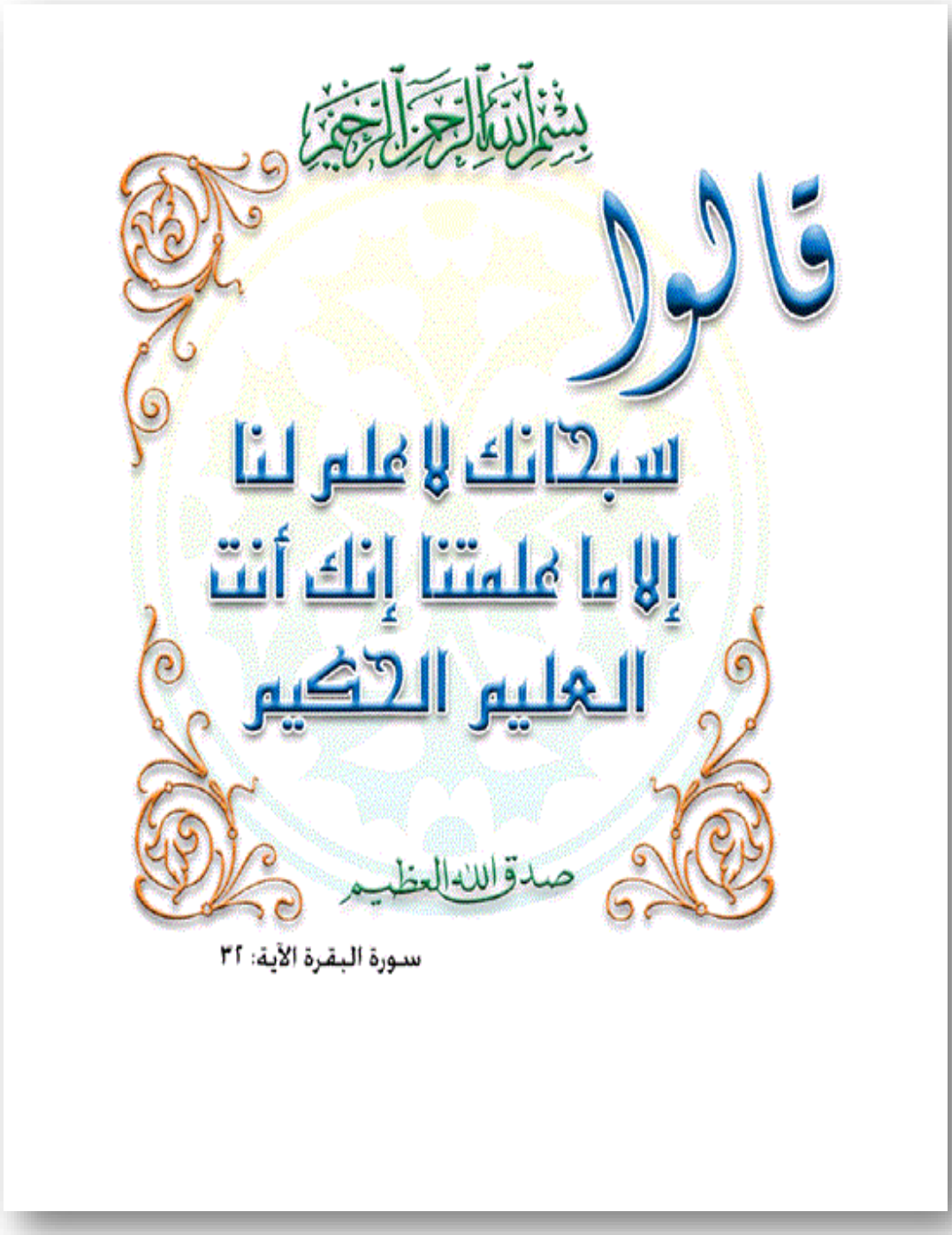
بسم الله الرحمن الرحيم
قالوا
سبحانك لا علم لنا
إلا ما علمتنا إنك أنت
العليم الحكيم
صدق الله العظيم
سورة البقرة الآية: ٣٢

Acknowledgement

First and foremost, my deep gratefulness and indebtedness is to Allah, the Most Gracious and the Most Merciful.

I would like to express my deepest appreciation and respect to Prof, Dr. Rania Aly Marouf Professor of Radiodiagnosis, Faculty of Medicine- Ain Shams University, for her generous guidance and patience.

I am grateful to Dr. Merhan Ahmed Nasr Lecture of Radiodiagnosis, Faculty of Medicine- Ain Shams University, for her effort and patiency.

My deep appreciation to Dr. Marwa El Sayed Abd El-Rahman, Lecturer of Radiodiagnosis, Faculty of medicine-Ain Shams University, for her sincere guidance and great effort during this study.

Lastly and not least, I send my deepest love to my family for their love and care.

Rana Mamdouh

LIST OF THE CONTENTS

- List of Abbreviations…….....i
- List of figures…….…..iii
- List of tables…….....vi
- Introduction and aim of the work ……..……1
- Review of literature.....4
  - Anatomy of the breast …….....4
  - Pathology of most common breast diseases ……..…14
  - Technique & interpretation of tomosynthesis ……...38
- Patients and Methods 72
- Results.....75
- Illustrative cases.....91
- Discussion.....100
- Conclusion & recommendations 106
- References 107
- Arabic Summary 116

LIST OF ABBREVIATIONS

FFDM	Full-field digital mammography
BIRADS	Breast imaging reporting and data system
DBT	Digital breast tomosynthesis
TDLU	Terminal ductal-lobular unit
AMF	Anterior mammary fascia
PMF	Posterior mammary fascia
ASL	Anterior suspensory ligament
HPL	Human placental lactogen
IGM	Idiopathic granulomatous mastitis
IDP	Intraductal papilloma
DCIS	Ductal carcinoma in situ
RR	Relative risk
LCIS	Lobular Carcinoma in Situ
IDC	Invasive ductal carcinoma
NOS	Not otherwise specified
NST	No special type

EIC	Extensive intraductal carcinoma
AJCC	American Joint Commission on Cancer
IUCC	International Union for Cancer Control
CC	Craniocaudal
DBT	Digital breast tomosynthesis
FFDM	Full field digital mammography
MLO	Mediolateral oblique
SM	Synthetic mammography
FDA	Food and Drug Administration
DM	Digital mammography
ACR	American College of Radiology

LIST OF FIGURES

Figures No.	Title	Page No.
Figure 1.1	Component of the breast	**4**
Figure 1.2	Illustration of Terminal Ductal Lobular Unit (TDLU)	**5**
Figure 1.3	Normal ultrasound breast anatomy	**7**
Figure 1.4	Sagittal Tl C + breast MR demonstrating zonal anatomy	**8**
Figure 1.5	Arrangement of the axillary lymph nodes	**10**
Figure 1. 6	lymphatic drainage of the breast	**11**
Figure 1.7	Normal mammographic breast anatomy	**13**
Figure 2.1	Chronic breast abscess	**16**
Figure 2.2	mammographic calcification of duct Ectasia	**17**
Figure 2.3	Mammographic appearance of fibrocystic disease	**20**
Figure 2.4	Mammogram of bilateral multiple fibroadenomas	**22**
Figure 2.5	Mammographic & US appearance of a benign phyllodes tumor	**23**
Figure 2.6	Mammographic appearance of a radial scar with magnification view	**25**
Figure. 2.7	Mammographic appearance of sclerosing adenosis	**27**
Figure. 2.8	a solitary benign intraductal papilloma	**28**

Figure 2.9	TNM staging of breast carcinoma	**37**
Figure 3.1	Diagram of DBT image acquisition	**39**
Figure 3. 2	Mediolateral oblique views of left breast in 57-year-old woman recalled after mammographic screening because of a spiculated mass	**42**
Figure 3.3	Illustration of breast composition according to ACR density scores	**44**
Figure 3.4	mammogram of dense breasts showing lateral asymmetric focal density. Tomosynthesis reveals spiculated margins	**45**
Figure 3.5	Contralateral breast cancer detected in DBT and MRI not observed in mammography	**48**
Figure 3.6	Asymmetric focal density by mammography found to be spiculated using tomosynthesis , Subsequent analysis showed it to be IDC	**49**
Figure 3.7	tomosynthesis confirmed an intramammary lymph node with medial architectural distortion that was subsequently diagnosed as contralateral IDC	**50**
Figure 3.8	Tomosynthesis reveals cutanouse navus by its smooth margins and enhanced rim, and demonstrates its cutaneous location	**51**
Figure 3.9	mammogram showing asymmetric density that was better detected by DBT with associated lateral architectural distortion	**52**
Figure 3.10	Breast IDC seen only at DBT at routine screening	**53**
Figure 3.11	Cancer seen only at DBT at routine screening of a 46-year-old woman.	**54**
Figure 3.12	Invasive ductal carcinoma manifesting as architectural distortion in dense breast tissue	**56**
Figure 3.13	Complex sclerosing lesion manifesting as architectural distortion	**57**
Figure 3.14	Tomosynthesis used to improve localization and guide targeted US of two areas of architectural distortion	**59**

Figure 3.15	Tomosynthesis localization guided US evaluation	**60**
Figure 3.16	Use of spot compression tomosynthesis to increase the conspicuity of subtle architectural distortion	**61**
Figure 3.17	case of invasive lobular carcinoma, MLO full-field tomosynthesis image shows an architectural distortion	**62**
Figure 3.18	micro calcifications are best seen on the synthetic 2D image ("highlighting") and the desmoplastic reaction is seen only on DBT.	**70**
Figure 3.19	Screening mammography of left breast &Synthetic 2D image shows segmental-linear calcifications highly suspicious for high-grade DCIS	**70**
Figure 3.20	A mass with large surrounding specula is easily seen on synthetic 2D and DBT but can't be seen even in retrospect conventional mammography.	**71**
Figure 5.1	the distribution of different breast densities among different age groups	**77**
Figure 5.2	Effect of addition of DBT to FFDM on BIRADS in diagnostic and screening setup	**81**
Figure 5.3	Effect of addition of DBT to FFDM on BIRADS scoring in different breast densities in diagnostic and screening setup	**85**
Figure 5.4	Effect of addition of DBT to FFDM on BIRADS scoring in different age groups in diagnostic and screening setup	**90**

LIST OF TABLES

Table No.	Title	Page No.
Table 3.1	BIRADS (ACR) classification of breast composition	**43**
Table 3.2	BIRADS assessment categories by mammography	**67**
Table 5.1	Breast density wise distribution of the study population	**76**
Table 5.2	Age wise distribution of the study population	**76**
Table 5.3	Percentage of BIRADS scoring of breast lesions on FFDM in diagnostic and screening groups	**77&78**
Table 5.4	Percentage of BIRADS scoring of breast lesions on DBT in diagnostic and screening groups	**78**
Table 5.5	Diagnostic performance of FFDM & DBT	**79**
Table 5.6	Diagnostic indices of FFDM & DBT	**79&80**
Table 5.7	Effect of addition of DBT to FFDM on BIRADS in diagnostic and screening setup	**80**
Table 5.8	Comparison of FFDM versus DBT according to BIRADS scoring in detection of breast lesions in fatty breast densities	**81&82**
Table 5.9	Comparison of FFDM versus DBT according to BIRADS scoring in detection of breast lesions in scattered fibroglandular breast densities	**82&83**
Table 5.10	Comparison of FFDM versus DBT according to BIRADS scoring in detection of breast lesions in heterogenouse breast densities	**83**
Table 5.11	Comparison of FFDM versus DBT according to BIRADS scoring in detection of breast lesions in extremely dense breast	**84**
Table 5.12	Effect of addition of DBT to FFDM on BIRADS scoring in different breast densities in diagnostic and screening setup	**85**

Table 5.13	Comparison of diagnostic indices of mammography and tomosynthesis in different densities	**86**
Table 5.14	Comparison of FFDM versus DBT according to BIRADS scoring in detection of breast lesions in age group (30 y – 40 y)	**86&87**
Table 5.15	Comparison of FFDM versus DBT according to BIRADS scoring in detection of breast lesions in age group (41-50)	**87**
Table 5.16	Comparison of FFDM versus DBT according to BIRADS scoring in detection of breast lesions in age group (51 y -60 y)	**88**
Table 5.17	Comparison of FFDM versus DBT according to BIRADS scoring in detection of breast lesions in age group (61 y-70 y)	**89**
Table 5.18	Effect of addition of DBT to FFDM on BIRADS scoring in different age groups in diagnostic and screening setup	**89&90**
Table 5.19	Comparison of diagnostic indices of mammography and tomosynthesis in different age groups	**90**
Table 5.20	Sensitivity of calcification detection of FFDM & DBT and synthetic 2D images	**91**

INTRODUCTION

Breast cancer incidence rates have increased by 20% with a possible increase of diagnosis before the age of 50. The pursuit of accurate and cost-effective ways to diagnose breast cancer early remains of interest. ***(Siegel et al, 2013)***

Cancer care has become more individualized for our patients, and thus, better characterization for treatment planning is required. Imaging examination plays an important tool in cancer detection &diagnosis and determination the response to therapy. ***(Jae-Hun et al, 2017)***

Screening mammography has long been considered as the primary technique in breast cancer detection and assessment. It is considered the most important screening tool for breast cancer. Reduction in mortality among age group of 40 years of age or older caused by breast cancer has been seen in various studies where screening mammography was used. ***(Tabar et al, 2011)***

Initially, screen film mammography was done and was the standard technique in breast cancer screening for many years, but today the most common imaging procedure ,gradually replacing film screen ,is a two-view examination (medio-lateral oblique and cranio-caudal) using full-field digital mammography (FFDM). Searching for any mass, architectural distortion, or calcification, and then accordingly give BIRADS score (Breast imaging reporting and data system). ***(Lewin et al, 2007)***

Nevertheless, mammography suffers from several limitations, primarily due to reduced contrast between tumors and surrounding tissue. Especially in dense breasts, this can lead to a decrease in sensitivity and additional imaging methods are necessary. ***(Emaus et al, 2015)***

Advances in full-field digital mammography (FFDM) led to the