✓ ok on disk

MRI AND CT EVALUATION OF THE CRANIOVERTEBRAL AND CERVICOMEDULLARY JUNCTION LESIONS

Thesis
Submitted for fulfillment for
The MD. Degree
In
Radiodiagnosis
By

Sameh Abd AL-Raouf Mahdy
M.B.B. Ch, M.Sc.

63628

616.07548
S. A

Supervised by

Prof. Dr. Zeinab Mohamed Abd Allah
Professor of Radiodiagnosis
Faculty of Medicine
Ain Shams University

Prof. Dr. Hossam Mohamed Al Hosseiny
Professor of Neurosurgery
Faculty of Medicine
Ain Shams University

Dr. Ahmed Mohamed Monib
Lecturer of Radiodiagnosis
Faculty of Medicine
Ain Shams University

Faculty of Medicine
Ain Shams University
1998

Central Library - Ain Shams University

Central Library - Ain Shams University

بسم الله الرحمن الرحيم

Central Library - Ain Shams University

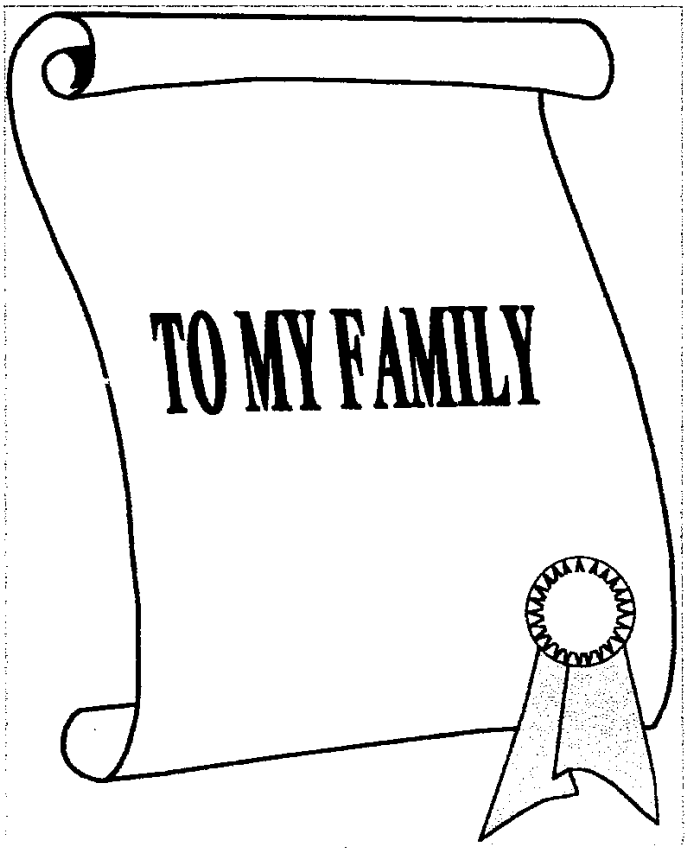

Central Library - Ain Shams University

Central Library - Ain Shams University

ACKNOWLEDGMENT

Thanks to ALLAH who is always helping me in life.

The credit of bringing this work to light goes to the masterly teaching our Professor Dr; Zeinab M.Abd - Allah Prof of Radiodiagnosis Ain Shams University.

A great deal of gratitude should be saved to. Dr. Ahmed M. Monib Lecturer of Radiodiagnosis Ain Shams University for his kind supervision, generous help and valuable pieces of advice, for him no words of praise are sufficient.

My deep appreciation goes to Prof. Dr; Hossam M.Al Hosseiny Professor of Neurosurgery Ain Shams University for his nice and sincere cooperation.

Last but not least, I would like to express my thanks to all my professors, colleagues and staff members of Radiodiagnosis department Ain Shams University and the team work of the MRI unit in ASUSH with sincere gratitude going to all of them.

Sameh

Central Library - Ain Shams University

Central Library - Ain Shams University

Abstract

Between June 1996 and September 1998, 111 patients with various C.M.J & C.V.J. abnormalities, they were 68 males and 43 females. Their ages ranged from 2 months and 70 years old .62 patients were examined by M.R.I, 9 patients were examined by C.T. and 40 patients were by CT & MRI. MRI proved to be the imaging modality of choice in evaluation of C.M.J. & C.V.J regardless the offending pathology, meantime C.T. is the imaging modality of choice of traumatic fractures.

Central Library - Ain Shams University

Central Library - Ain Shams University

Contents

	Page
• Introduction And Aim Of The Work.	1
• Anatomy.	3
• Pathology.	26
• Subject And Methods.	70
• Results	75
• Selected Cases With Illustrations.	117
• Discussion.	158
• Summary And Conclusion.	172
• References.	175
• Arabic Summary.	---

Central Library - Ain Shams University

Central Library - Ain Shams University

List of Figures *Page*

1. Anterior surface of the brain stem 3
2. Posterior view of the brain stem. 3
3. Diagram showing the spino -cerebellar tracts. 6
4. Diagram showing the spino-thalamic tracts. 7
5. Course and communication of the vertebral arteries. 12
6. The atlas vertebra. 10
7. The axis vertebra. 11
8. Ligaments of the joints of atlas. 12
9. Ligaments of the joints of atlas. 14
10. a-b sagittal T1WI for the brain stem. 17
11. Axial T2 WI for the brain stem. 18-19
12. Normal landmarks needed to asses C.V.J relationships. 20
13. Chamberlain line. 21
14. a-Wackenheim clivus base line. 22
- b-Welcher basal angle.
15. Atlanto-occipital joint axis angle. 22
16. The atlas. 24
17. Atlanto-occipital articulation. 24
18. Posterior arch anomalies 43
19. Jefferson fracture. 59
20. Types of rotatory subluxation of C1 on C2 60
21. Types of occipital condylar fractures. 61
22. Types of dens fractures. 62
23. Hangman's fracture. 63
24. Chiari I malformation. 117
25. Chiari III malformation. 118
26. Dandy Walker syndrome. 119
27. Retro-cerebellar arachnoid cyst. 120
28. Aplasia of the posterior arch of C1. 121
29. Low grade brain stem glioma. 122-123
30. Brain stem glioma. 124-125
31. Brainstem glioma. 126-127
32. C.M.J. inta-medullary astrocytoma. 128
33. Left cerebellar astrocytoma. 129

Central Library - Ain Shams University

34. 4th ventricular ependymoma. 130-131
35. 4th ventricular haemangblastoma. 132
36. Clival chordoma with downward extension to C2. 133-134
37. Clival chordoma. 135
38. Vermian medulloblastoma. 136
39. Recurrent medulloblastoma with multiple cervical, dorsal, and lumbar leptomeningeal. 137
40. Osseous metastatic deposits. 138
41. Miliary metastasis. 139
42. Retro-clival creeping meningioma. 140-141
43. Foramen magnum meningioma. 142
44. Intradural meningioma 143
45. Left CPA epidermoid 144
46. Brainstem hemorrhage. 145-146
47. Left P.I.C.A. territory infarction. 147
48. Uncomplicated A.V.M. 148
49. Displaced fracture of the dens Type III. 149-150
50. Typical type 3 Jefferson fracture. 151
51. Type II displaced fracture with C.M.J. 152
52. Post traumatic myelomalacia. 153
53. Tuberculous meningitis. 154
54. Rheumatoid arthritis pannus at the atlanto-axial joint 156-155
55. Multiple cerebral and spinal cord M.S. plaques. 157

Central Library - Ain Shams University

List of abbreviations

A.V.M.	Arterio venous malformation.
B.A.	Basilar artery.
C.M.J.	Cervicomedullary junction.
C.N.S.	Central nervous system.
C.V.J.	Cranio-vertebral junction.
C.P.A.	Cerebellopontine angle.
C.T.	Computed tomography.
C.S.F.	Cerebro-spinal fluid.
C.T.M.	C.T with intrathecal contrast (myelography).
E.T.L.	Echo train length.
F.	Female.
F.C.	Flow compensation.
F.M.	Foramen magnum.
F.M.P.S PGR	Fast multiplanar spoiled grass.
Gd-DTPA.	Gadolinium-diethylene-triamine penta acetic acid.
G.R.E.	Gradient refocused echo.
I.C.P.	Intra cranial pressure.
M.R.I.	Magnetic resonance imaging.
M.	Male
M.C.A.	Motor car accident
M.O.	Medulla oblongata.
M.S.	Multiple Sclerosis.
N.E.X.	Number of excitation.
P.D.	Proton density.
PICA	Posterior inferior cerebellar artery.
R.A.	Rheumatoid arthritis.
S.A.H	Subarachnoid hemorrhage

Central Library - Ain Shams University

SNHL	Sensory neural hearing loss.
T.E.	Time of echo.
T.R	Time of repetition.
T1 WI	T1 weighted images.
T2 WI	T2 weighted images.
V.A.	Vertebral artery.
V.B.S.	Vertebro -basilar system.
**	Marking the selected cases in the master table.

Central Library - Ain Shams University