Role of Multiplane Transesophageal Echocardiographic Examination In Assessing Mitral Regurgitation By Doppler Colour Flow Mapping

Thesis
Submitted In Partial Fulfilment of
The Master Degree In Cardiology

By

Walaa Adel Abdel Haleem Mahmoud
M.B., B.Ch.

616.1250754 3
W. A
53749

Supervised By

Prof. Dr. Mohammed Khairy Abdel Dayem
Professor of Cardiology
Faculty of Medicine - Ain Shams University

Dr. Mervat Aboul Maaty Nabih
Assistant Professor of Cardiology
Faculty of Medicine - Ain Shams University

Faculty of Medicine
Ain Shams University

1997

Central Library - Ain Shams University

Central Library - Ain Shams University

بسم الله الرحمن الرحيم

Central Library - Ain Shams University

بسم الله الرحمن الرحيم

﴿وقل اعملوا فسيرى الله عملكم
ورسوله والمؤمنون﴾

صدق الله العظيم

Central Library - Ain Shams University

Central Library - Ain Shams University

Central Library - Ain Shams University

Central Library - Ain Shams University

Acknowledgment

It is a great thing to feel success and have the pride of achieving all what is always aspired. Nevertheless, one must not forget all those who usually help and push him onto the most righteous way that inevitably ends with fulfillment and perfection.

When the instant comes to appreciate all those kind-hearted people, I soon mention Prof. Dr. Khairy Abdel Dayem, Professor of Cardiology, Ain Shams University, the person who gave me the honor by reading every word written in this thesis. He really helped me by his precious opinions and contributive comments that served much in the construction of this work.

Thanks are also due to Dr. Mervat Aboul Maaty, Assistant Professor of Cardiology, Ain Shams University,. who has been the real sister who always supports, encourages and gives the fruitful ideas, suggestions and constructive pieces of advice.

My sincere thanks are likewise to all the technicians in the catheter lab of Ain Shams University Hospital, for helping me throughout the practical part of this work.

Central Library - Ain Shams University

Central Library - Ain Shams University

TABLE OF CONTENTS

INTRODUCTION 1

AIM OF THE WORK 3

REVIEW OF LITERATURE 4

CHAPTER (1): ANATOMY AND PATHOLOGY OF MITRAL VALVE APPRATUS 4

1. Abnormalities Of Valve Leaflets. 8
2. Abnormalities Of The Mitral Annulus 9
3. Abnormalities Of The Chordae Tendineae. 12
4. Involvement Of The Papillary Muscles 13
5. Left Ventricular Abnormalities 14

CHAPTER (2): ASSESSMENT OF MITRAL REGURGITATION 15

A. TRANSTHORACIC ECHOCARDIOGRAPHY 15

Pulsed Doppler 16
Continuous wave Doppler: 19
Color Flow Imaging 19

B. TRANSESOPHAGEAL ECHOCARDIOGRAPHY 31

Pulsed Doppler 31
Color Flow Doppler 34

C. CARDIAC CATHETERIZATION 43

Hemodynamic Assessments 43
Angiographic Assessment 44

CHAPTER (3): MULTIPLANE TRANSESOPHAGEAL ECHOCARDIOGRAPHY 48

Comparison of monoplane, biplane, and multiplane transesophageal echocardiography 49
Multiplane Transesophageal Echocardiography Image Notation.. 52
Instrumentation 53

Central Library - Ain Shams University

SYSTEMATIC MULTIPLANE TRANSESOPHAGEAL ECHOCARDIOGRAPHIC EXAMINATION ***55***
1. Setup 55
2. Endoscope Insertion 56
3. Multiplane Views 56
4. Longitudinal Views 57
5. Four-Chamber Views 58
6. Multiplane Apical Views 59
7. Transgastric Longitudinal Views 60
8. Transgastric Multiplane Views 60
9. Pulmonary Artery Bifurcation 62
10. Left Atrial Appendage and Pulmonary Veins 63
11. Thoracic Aorta 65
CLINICAL APPLICATION OF MULTIPLANE TRANSESOPHAGEAL ECHOCARDIOGRAPHY ***65***
Short- and Long-Axis Views of the Aortic Valve 65
Long-Axis View of the Left Ventricular Outflow 67
Transgastric Multiplane Images 67
Short- to Long-Axis Scans 68
360-Degree Rotation 68
LIMITATIONS OF MULTIPLANE TECHNOLOGY ***69***

SUBJECTS AND METHODS **70**

SUBJECTS **70**

Patient selection: 70
Inclusion criteria 70
Exclusion criteria 70

METHODS **71**

1) FULL HISTORY TAKING AND THOROUGH CLINICAL EXAMINATION: 71
2) TRANSTHORACIC ECHOCARDIOGRAPHY 72
3) TRANSESOPHAGEAL ECHOCARDIOGRAPHY 74
4) LEFT VENTRICULOGRAPHY 80

STATISTICAL METHODS **81**

DATA COLLECTION SHEET **84**

Central Library - Ain Shams University

RESULTS **85**

CLINICAL CHARACTERISTICS: ***85***
CARDIAC CATHETERIZATION ***86***
ASSESSMENT OF MITRAL REGURGITATION BY CONVENTIONAL JET AREA METHOD ***86***
a) Transthoracic examination 86
b. Biplane transesophageal echocardiography: 88
ASSESSMENT OF MITRAL REGURGITATION BY VENA CONTRACTA METHOD BY MULTIPLANE TEE ***90***
a) Transverse plane (0°) 90
b) Longitudinal plane (90°) 91
c) Two-chamber plane (30°-60°) 93
d) Long-axis plane (120°-150°) 94
IMPACT OF JET ECCENTRICITY ON PARAMETERS USED TO ASSESS SEVERITY OF MITRAL REGURGITATION ***95***
CASE PRESENTATIONS ***98***

DISCUSSION **102**

JET AREA METHOD ***102***
VENA CONTRACTA METHOD ***105***
CLINICAL IMPLICATIONS ***111***
STUDY LIMITATIONS ***112***

CONCLUSION **113**

RECOMMENDATIONS **115**

SUMMARY **116**

REFERENCES **124**

APPENDICES **135**

ARABIC SUMMARY

Central Library - Ain Shams University

Central Library - Ain Shams University

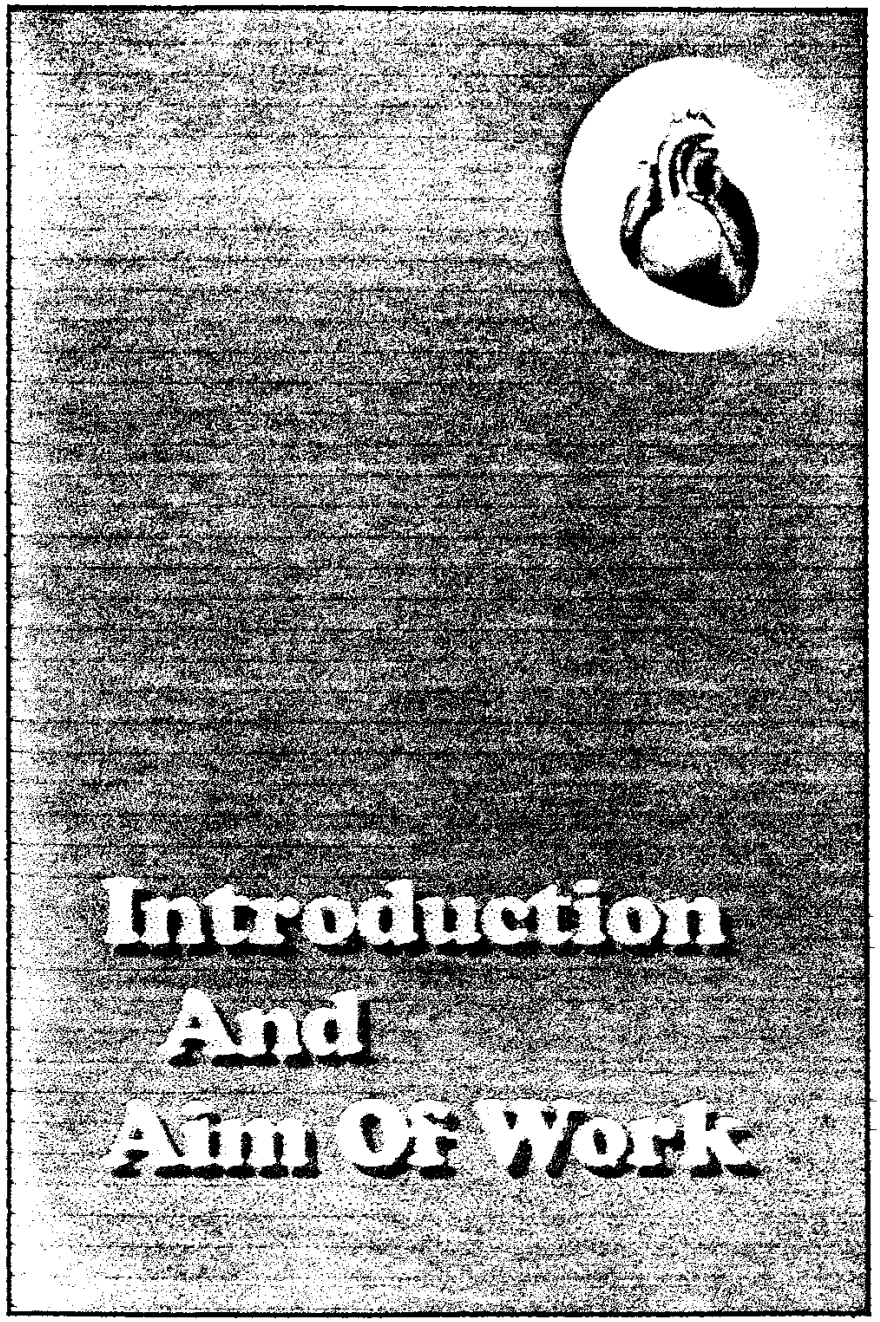

Central Library - Ain Shams University

Central Library - Ain Shams University