



THE ROLE OF STEREOTAXY IN LOCALIZATION OF CRANIOTOMIES

THESES

Submitted for partial fulfillment of
The M. Sc Degree
in
GENERAL SURGERY

Presented by
Mahmoud Hamdy Ibrahim
M.B., B.Ch

617.481
M. H

Under Supervision Of:

PROF. DR. ALAA ABDELHAY
Professor of Neurosurgery
Faculty of Medicine
Ain Shams University

DR. AHMAD HAMAD
Lecturer of Neurosurgery
Faculty of Medicine
Ain Shams University


DR. HUSSEIN MOHARRAM
Lecturer of Neurosurgery
Faculty of Medicine
Ain Shams University

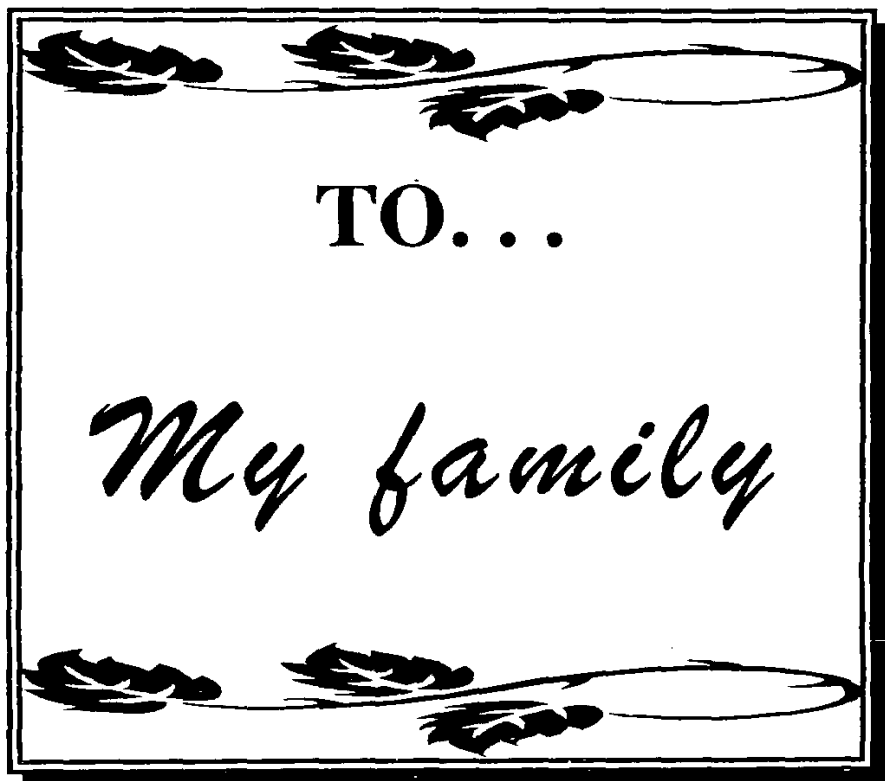
**FACULTY OF MEDICINE
AIN SHAMS UNIVERSITY
CAIRO 1998**

547.2









ACKNOWLEDGMENT

To ALLAH, goes all my deepest gratitude and thanks for achieving any work in my life.

*I wish to express my cordial appreciation and utmost gratitude to **Professor Dr. Alaa El-Din Abd El-Hay**, Professor of Neurosurgery, Ain Shams University, for his sincere guidance, supervision and kind encouragement throughout the whole thesis. Professor Hay was the body and core of this study by his energetic and scientific way of dealing with every task. His perservance and nobel way of teaching were and still are unmatched, to him, I owe a lot.*

*My sincere thanks to **Dr. Ahmed Hamad**, Lecturer of Neurosurgery, Ain Shams University. for initiating the idea for this thesis, as well as providing an invaluable criticism and direction.*

*I am indeed most grateful to **Dr. Hussein Moharram**, Lecturer of Neurosurgery, Ain Shams University, for his relentless support, splendid efforts and creative thoughts.*

Last but not least, my deep appreciation is expressed to all the staff of Neurosurgery Department, Ain shams University, and to all members of my family for their co-operation and encouragement.

INDEX

Part	Subject	Page
I	Introduction and Aim of the work	1
II	Review of Literature	
	• Indications	3
	• Advantages	7
	• Anatomy of the cerebral cortex	10
	• Principles of stereotaxy	22
	• Volumetric CT/MRI based stereotaxy	31
	• Frameless stereotaxy	39
	• Procedural aspects of stereotactic craniotomy	45
	• Pathology	50
III	Patients and Methods	65
IV	Results	80
V	Discussion	110
VI	Summary and conclusion	119
VII	References	122
VIII	Arabic summary	---

LIST OF TABLES

No.	Title	Page
1	Age incidence and number of patients	80
2	Clinical presentation of patients	82
3	Size of different lesions	85
4	Distance from the surface of lesion to the brain surface	86
5	Indications of stereotactic craniotomy	88
6	Pathological diagnosis of different cases	91
7	Extent of excision of various lesions	100
8	Average time of surgery in different cases operated on by stereotactic craniotomy	101
9	Size of craniotomy in different cases following stereotactic craniotomy	103
10	Clinical outcome in relation to different affected cerebral lobes	105
11	Clinical outcome in relation to different pathologies	106
12	Average time of hospital stay in different pathologies following stereotactic craniotomy	108

LIST OF FIGURES

No.	Title	Page
1	The superolateral surface of the left cerebral hemisphere. Lateral aspect	10
2	The orbital surface of the left frontal lobe	11
3	The motor homunculus	12
4	The superolateral surface of the left cerebral hemisphere. Superior aspect	13
5	The sensory homunculus	14
6	The areas of localisation on the medial surface of the left cerebral hemisphere	17
7	The CRW head ring	24
8	Method of calculation in the fiducial reference system	27
9	Action of the fiducial reference system	27
10	Drawing of a typical arc-quadrant for a stereotactic frame. Showing collar angle and arc angle.	30
11	Simplified COMPASS stereotactic frame	33
12	Illustration of method employed for the volumetric stereotactic resection of a superficial tumour	37
13	Illustration of method employed for the volumetric stereotactic resection of a deep seated tumour	38
14 a-f	Illustration of procedural aspects of frameless stereotaxy	41
15	Type I glial neoplasms	50
16	Type II glial neoplasms	51
17	Type III glial neoplasms	52

(Continued)

(Continued)

18	Preparation of the table before starting the procedure of stereotaxy	68
19	Illustration of base ring placement to avoid obstruction of access to the lesion	69
20	Patient with base ring of CRW system fixed to the head	70
21	CRW localizer system fixed to the base ring	71
22	Riechert-Mudinger localizer system fixed to the base ring	71
23	The computer console that was used in measuring the X and Y dimensions of each fiducial point	72
24	The digitizer of the Riechert-Mudinger system	73
25 a,b	a. The programmable printing calculator of the CRW system. b. The lap top computer of the Riechert-Mudinger system	74
26 a,b	a. Phantom base and arc of the CRW system b. Phantom base of the Riechert-Mudinger system	76
27 a-c	Illustration of steps of craniotomy guided by the test needle	77
28	Number of patients in different decades	81
29	Sex distribution	81
30	Clinical presentation of patients	82
31	An example of a case presented by Rt hemiparesis	83
32	An example of a case presented by fits	83
33	Distribution of lesions in different cerebral lobes	84
34	Size of lesions	85

(Continued)