HISTOPATHOLOGICAL CLASSIFICATION OF TUMORS OF THE EXTRAHEPATIC BILE DUCTS

Thesis Submitted for the Partial Fulfillment of the Master Degree of Pathology

By

Doaa Ahmed Ibrahim

M.B., B.Ch.

54802

Supervised by

Prof. Dr. Talaat El-Deeb

Professor of Pathology
Faculty of Medicine-Ain Shams University

Prof. Dr. Karima Fahmy Sidhom

Professor of Pathology
Faculty of Medicine-Ain Shams University

Dr. Sahar Saad El-Deen

Assistant Professor of Pathology
Faculty of Medicine-Ain Shams University

Faculty of Medicine
Ain Shams University
1997

Central Library - Ain Shams University

Central Library - Ain Shams University

بسم الله الرحمن الرحيم

Central Library - Ain Shams University

بسم الله الرحمن الرحيم

قالوا سبحانك لا علم لنا إلا ما علمتنا،

إنك أنت العليم الحكيم

صدق الله العظيم

سورة البقرة، الآية ٣٢

Central Library - Ain Shams University

Central Library - Ain Shams University

Acknowledgment

I would like to express my deepest gratitude to Prof. Dr. Talaat El-Deeb, Professor of Pathology, Ain Shams University, for making this work possible, and for his constant support.

I sincerely thank Prof. Dr. Karima Sidhom, Professor of Pathology, Ain Shams University, for her enormous support and advice.

I am also very grateful to Dr. Sahar Saad El-Dean, Assistant Professor of Pathology, Ain Shams University, for her valuable direction and guidance.

I would like to thank Prof. Dr. Mohammed El-Shawarby, Professor of Pathology, Ain Shams University, for his help in the collection of the material of this work.

Central Library - Ain Shams University

Central Library - Ain Shams University

List of Contents

	Page
Introduction and aim of the work	**1**
Review of literature	**4**
• Anatomy of the biliary tract	4
• Histology of the bile ducts	7
• Histopathological classification of extrahepatic bile duct tumors	9
• Pathology of extrahepatic bile duct tumors	
➢*Incidence of extrahepatic bile duct tumors*	*26*
➢*Anatomic location of bile duct tumors*	*27*
➢*Gross appearance of bile duct tumors*	*28*
➢*Microscopic picture of bile duct tumors*	*31*
➢*Clinical presentation of extrahepatic bile duct tumors*	*42*
➢*Associated disease*	*44*
➢*Diagnosis of extrahepatic bile duct tumors*	*44*
➢*Prognosis and survival*	*45*
Material and Methods	**47**
Results	**48**
Discussion	**68**
Summary and Conclusion	**73**
References	**76**
Arabic Summary	

Central Library - Ain Shams University

Central Library - Ain Shams University

List of figures

Page

- Fig. (1): Diagram of anatomy of the biliary tract *6*
- Fig. (2): Showing well differentiated, mucous secreting adenocarcinoma (H&E × 250). *56*
- Fig. (3): Showing well differentiated adenocarcinoma (H&E × 250). *57*
- Fig. (4): Showing well differentiated, mucous secreting adenocarcinoma (H&E × 100). *58*
- Fig. (5): Showing moderately differentiated adenocarcinoma (H&E × 250). *59*
- Fig. (6): Showing moderately differentiated, mucous secreting adenocarcinoma (H&E × 250). *60*
- Fig. (7): Showing moderately differentiated, mucous secreting adenocarcinoma (H&E × 250). *61*
- Fig. (8): Showing poorly differentiated adenocarcinoma (H&E × 250). *62*
- Fig. (9): Showing poorly differentiated, mucous secreting adnocarcinoma (H&E × 250). *63*
- Fig. (10): Showing well differentiated adenocarcinoma with giant cell reaction (H&E × 100). *64*
- Fig. (11): Showing well differentiated adenocarcinoma with fibromuscular infiltration (H&E × 100). *65*
- Fig. (12): Showing fibromuscular infiltration (H&E × 100). *66*
- Fig. (13): Showing the perineural invasion (H&E × 250). *67*

Central Library - Ain Shams University

Central Library - Ain Shams University

List of tables

Page

- **Table (1):** Age and sex distribution of extrahepatic bile ducts carcinoma *53*
- **Table (2):** The relation between gross appearance, tumor size and histopathological grading of adenocarcinoma cases *53*
- **Table (3):** Relation of histologic grading of cancer to the extent of infiltration *54*
- **Table (4):** Relation of gross appearance of cancer to the extent of infiltration *54*
- **Table (5):** Relation between gross appearance, histologic grading and infiltration *55*

Central Library - Ain Shams University

Central Library - Ain Shams University

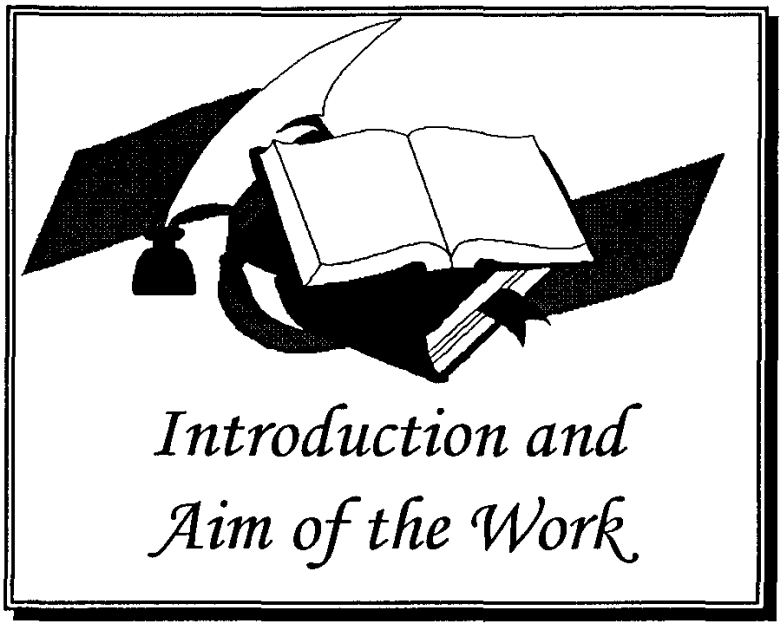

Introduction and Aim of the Work

Central Library - Ain Shams University

Central Library - Ain Shams University