

*Fixation of Fractures of The Humeral
Shaft
Using Interlocking Intramedullary Nails*

Thesis submitted for partial fulfilment
of M.D. Degree in orthopaedic surgery



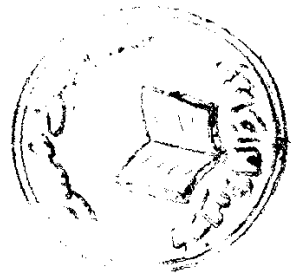
BY

Dr. Alaa Eldin Mohamed El Nabawy Youssef Mostafa

Under Supervision of

Prof. Dr. Osama Shata
Prof. of Orthopaedic Surgery
Faculty of Medicine
Ain Shams University

Prof. Dr. Sameh Shalaby
Prof. of Orthopaedic Surgery
Faculty of Medicine
Ain Shams University



Dr. Naser Zaher
Lecturer in Orthopaedic Surgery
Faculty of Medicine
Ain Shams University

Faculty of Medicine
Ain Shams University
1998



بِسْمِ اللَّهِ الرَّحْمَنِ الرَّحِيمِ
"قَالُوا سُبْحَانَكَ لَا عِلْمَ لَنَا
إِلَّا مَا عَلَّمْتَنَا إِنَّكَ أَنْتَ
الْعَلِيمُ الْحَكِيمُ"

البقرة آية ٣٢

ACKNOWLEDGMENT

I would like to express my deep respect & my thanks to Prof. Dr. Osama Shara to his keen guidance & priceless advice.

In addirtion, I would like to thank as well Prof. Dr. Sameh Shalaby for his continuous advice & his efforts. without him this work would have surely failed.

Also, I would like to thank Dr.Naser Zaher for his friendly attitude and his sincere guidance.

DEDICATION

To my beloved parents.

To my loving & caring wife.

ABSTRACT

This study included 40 humeral fractures in 39 patients. 32 were traumatic fractures and 8 were pathological. Two nails were used, Biomet in 28 fractures and Russell-Taylor in 12 fractures. Two techniques were used antegrade in 28 fractures and retrograde in 12 fractures.

Thirty of the traumatic fractures progressed to full union and two failed to unite. The final functional outcome was excellent in 28 patients, good in two patients and poor in two patients.

The eight patients who sustained pathological fractures regained useful function of their limbs and their pain relief was satisfactory.

The overall results of this technique was satisfactory and this method of treatment is valuable when the indication is justified.

Key words:

Humerus, interlocking nail, antegrade technique-retrograde technique.

CONTENTS

Introduction	1
Review of literature	3
Anatomy of the humerus	3
Blood supply of the humeral shaft	11
Vascular response of bone to fractures	15
Historical review	17
Biomechanics of intramedullary nailing	21
Fractures of the shaft of the humerus	35
Material and methods	37
Follow-up	87
Discussion	125
References	137
Summary	145



LIST OF FIGURES

Fig	Comment	Page
1.	C.T. study of the lower end of the humerus	6
2.	Relation of the radial nerve to the humerus	8
3.	Coronal section in an adult humerus	8
4.	Relation of the axillary nerve to the humerus	9
5.	Cross section of the diaphysis of long bone	12
6.	Blood supply of a long bone	12
7.	Modny nail	18
8.	Halloran nail	18
9.	Seidel nail	19
10.	Mechanical properties of materials	22
11.	Structural properties of materials	22
12.	Cross section of different types of nails	25
13.	Modulus of elasticity	26
14.	The working length principle	28
15.	Fatigue strength	29
16.	Notch sensitivity	29
17.	Torsion	32

Fig	Comment	Page
18.	Effect of muscle on the fracture configuration	35
19.	A.O. classification of diaphyseal humeral fractures	41
20.	Holstein-Lewis fracture	46
21.	Antegrade flexible nailing	50
22.	Retrograde flexible nailing	51
23.	Retrograde Hackethal nailing	52
24.	Sex distribution	57
25.	Side distribution	57
26.	Age distribution	58
27.	Classification of fractures	60
28.	Russell-Taylor nail	66
29.	Patient positioning "antegrade nailing"	69
30.	Anterior acromial approach	70
31.	Entry point for antegrade nailing	70
32.	Opening of the medullary canal	70
33.	Anatomical landmarks for the skin incision	74
34.	Exposure of the rotator cuff	74
35.	Opening of the medullary canal using drill bit	75