

RECURRENT DUODENAL ULCER

ESSAY

Submitted in Partial Fulfilment for the
Master Degree of General Surgery

Handwritten signature

By

Tarek Mohamed Farid Elbahar
M.B., B. Ch.

Supervised by

Prof. Dr. MOHI ELDIN SEDKY
Professor of Surgery

Handwritten signature


Faculty of Medicine Ain Shams University

1984

Handwritten signature

A C K N O W L E D G E M E N T

I would like to express my deep and sincere gratitude to Professor Dr. Mohi Al Din Sedky, Professor of Surgery, Ain Shams University, for his kind approval to register the subject of this essay. I am greatly impressed also for his continuous advice and close supervision.





C O N T E N T S

	Page
ACKNOWLEDGEMENT	
INTRODUCTION	1
ANATOMY OF THE STOMACH	2
PHYSIOLOGY OF THE STOMACH	16
SURGICAL PATHOLOGY OF RECURRENT PEPTIC ULCER	24
INCIDENCE OF RECURRENT PEPTIC ULCER	28
AETIOLOGY OF RECURRENT PEPTIC ULCER	31
CLINICAL PICTURE OF RECURRENT PEPTIC ULCER	38
INVESTIGATIONS OF RECURRENT PEPTIC ULCER	43
TREATMENT OF RECURRENT PEPTIC ULCER	51
SUMMARY	63
REFERENCES	64
ARABIC SUMMARY	

I N T R O D U C T I O N

With the modern civilization, Peptic ulcer disease is becoming a significant cause of morbidity. There is an increasing number of patients attending hospitals and out patient clinics seeking for medical advise, follow up, investigations and treatment for this condition. Surgery has a good record for its contribution to the management of peptic ulcer disease. The majority of patients treated surgically are cured of their symptoms and remians ever grateful to their surgeon, but one of the most distressing surgical complication is recurrence, which may cause further morbidity and even mortality.

Recurrent peptic ulcer is a big problem that merits studing and research. The aim of this work is to study briefly recurrent peptic ulcer as regard incidence, aetiology, clinical picture, investigations and both medical and surgical treatment of recurrent peptic ulcer.

Finally, we hope that this study might offer some help in dealing with such condition.

REVIEW OF LITERATURE

ANATOMY OF THE STOMACH

The stomach is the reservoir of the digestive system. It is the most dilated part of the digestive tube, its varies with age, measuring about 30 - 40 ml at birth and increases gradually in size reaching about 1000 ml at puberty and finally about 1500 ml in the mature adult.

The stomach begins immediately after the oesophagus and ends in the duodenum. It lies in the epigastrium, left hypochondrium and umbilical regions. Actually its shape and position vary according to its degree of filling and according to the condition of the surrounding visera.

Parts Of The Stomach:

The stomach consists of fundus, body, pyloric region and pylorus. The fundus is that part of the stomach which projects upwards above level of the cardiac orifice, being in contact with the left cupula of diaphragm. The fundus continues downwards as the body which extends till a notch along the lower part of the lesser curvature which is called incisura angularis. From this level extends the pyloric antrum till the pylorus.

The pylorus is palpably thicker than the rest of the stomach wall and the pyloric canal is held closed by the

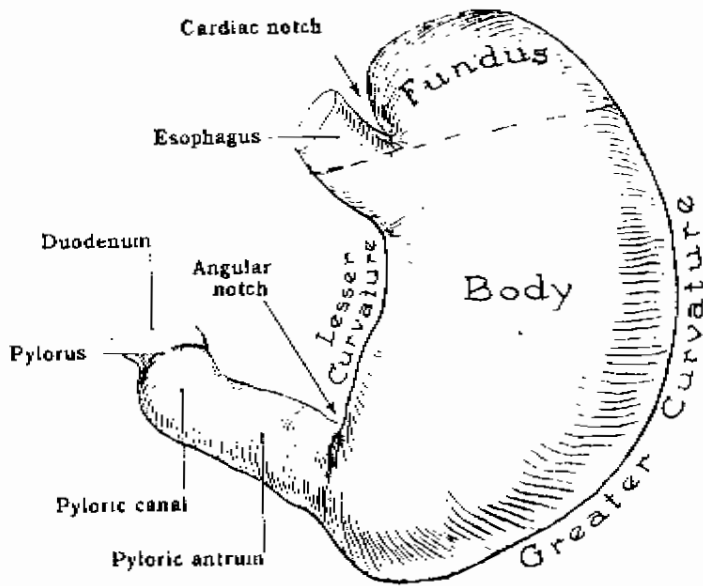


Fig. 1: Parts of the stomach.

tonus of the pyloric sphincter except when the latter relaxes to allow the stomach to expel a jet of its contents into the duodenum' (Last, 1977).

The Gastric Orifices:

First is the cardiac orifice which lies at the gastroesophageal junction. It lies slightly to the left of the mid-line behind the 7th costal cartilage, one inch from its junction with the sternum and at the level of 11th thoracic vertebra. It is 40 cm away from the incisor teeth and 10 cm deep to the anterior abdominal wall.

Second is the pyloric opening which opens into the duodenum. It lies about 1/2 inch to the right of mid-line and at the level of lower border of 1st lumbar vertebra (transpyloric plane). During operation it could be recognised by the prepyloric vein of Mayo and the thick pyloric sphincter.

The Gastric Surfaces:

The stomach has two surfaces, anterosuperior and posteroinferior surfaces. The anterosuperior surface is posterior to the left costal margin on its left part. It is in contact with the diaphragm, which separates it from

the left pleura, the base of the left lung, the pericardium and the 6th, 7th, 8th and 9th ribs and intercostal spaces of the left side, it is related to the costal attachment of the upper fibres of origin of the transversus abdominis. The upper and left part of this surface lies in contact with the gastric surface of the spleen. The right half is in relation with the left and quadrate lobes of the liver and with the anterior abdominal wall. When the stomach is empty, the transverse colon may lie on the front of this surface. The whole surface is covered with peritoneum and a part of the greater sac intervenes between it and the above structures.

The postero-inferior surface is related to the diaphragm, the left suprarenal gland, the upper part of the kidney, the splenic artery, the anterior surface of pancreas, the left colic flexure and the upper layer of the transverse mesocolon. These structures form the stomach bed, but the stomach is separated from them and can slide over them due to the intervening omental bursa. The gastric surface of the spleen is also described as part of the stomach bed, but it is separated from the stomach by a part of the greater sac. The greater omentum and the transverse mesocolon separate the stomach from the duodeno-jejunal flexure and small intestine.

The postero-inferior surface is covered with peritoneum, except near the cardiac orifice, where there is a small triangular area, in direct contact with the left crus of diaphragm, sometimes with the left suprarenal gland. The left gastric vessels reach the lesser curvature of the stomach at the right extremity of this area, and from its left side a short peritoneal fold, termed the gastro-phrenic ligament passes to the inferior surface of the diaphragm.

The Gastric Curvatures:

The stomach has two curvatures the lesser and greater curvatures. The lesser curvature forms the right border of the stomach. It descends as a continuation of the right margin of oesophagus in front of the decussating fibres of right crus of the diaphragm, and then, turning to the right, it curves below the omental tuberosity of the pancreas and ends at the pylorus. The most dependant part of the curve forms a notch, called the incisura angularis, which varies in position with the state of distension of the stomach but it is constantly present. The lesser curvature gives attachment to the layer of lesser omentum containing the right and left gastric vessels.

The greater curvature forms the left border of the stomach and it is 4-5 times as long as the lesser curvature. It begins at the cardiac orifice where it extends upwards from the cardiac notch between the fundus of the stomach and the lower end of the oesophagus. Then the greater curvature arches upwards, backwards and to the left to define the fundus, the highest point of it is on a level with the left fifth intercostal space just below the left nipple but this level varies with phases of respiration. Then the greater curvature curves downwards and forwards with a convexity downwards and to the left, and finally upwards and to the right till it ends at the pylorus. Directly opposite the angular notch the greater curvature forms a bulge which is the left extremity of the pyloric part of the stomach; this is limited on the right by a slight groove, which indicates the subdivision of the pyloric part into a pyloric antrum and pyloric canal. The latter is only 2-3 cm in length and terminates at the pyloric constriction. The greater curvature is covered at its beginning by the peritoneum continuous with that on the front of the stomach. On the left side of the fundus and adjoining part of the body, the greater curvature gives attachment to the gastrosplenic ligament, while its lower portion gives attachment to the two layers of greater omentum separated from each other by the gastro-epiploic

vessels. The gastrosplenic ligament and the greater omentum are directly continuous being parts of the original dorsal mesogastrium.

Structure Of The Stomach:

The peritoneum gives the stomach a complete serous coat, except along the curvatures and also over a small area which is in direct contact with the diaphragm, to the left of the cardiac orifice.

The muscular coat consists of three layers of involuntary muscle; an outer longitudinal, and intermediate circular, and an inner oblique stratum. The circular layer is greatly thickened at the pylorus to form the sphincter.

The mucous coat is thick and vascular. It is thrown into numerous folds which, in general, are longitudinal in direction and best marked along the greater curvature. These folds disappear when the stomach is distended. The mucous membrane along the lesser curvature is smooth, even when the stomach is empty. Two longitudinal folds, one on the anterior surface and the other on the posterior surface, lie near and in the line of lesser curvature, and it may be that the oblique fibres of the muscular coat participate in the formation

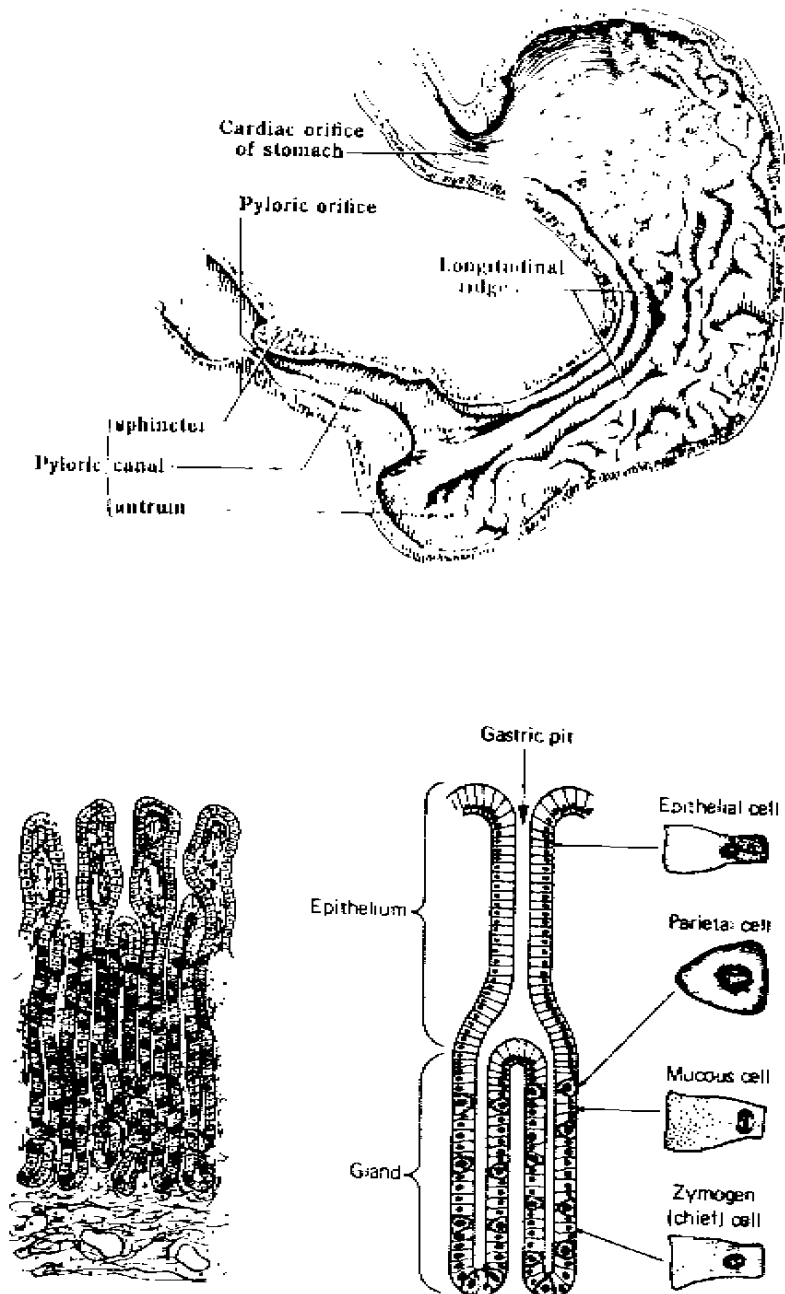


Fig. 2: Gross and microscopic appearance of the stomach mucosa.

of these folds. The edges of these folds come together when the stomach is empty and they therefore form a canal which leads from cardiac orifice to pyloric antrum. This canal has been termed the " gastric street " or " Magenstrasse ", and fluids - and perhaps food - may be conveyed to the pyloric end of the stomach along it.

Histology:

Mucous Cell:

They are found in big numbers in the gland specially at the neck. They secrete mucous which is heterogenous mixture of glycoproteins. The mucous provides a weak barrier to the diffusion of H^+ and probably protects the mucosa. It also acts as a lubricant and may impede diffusion of pepsin. (Dunphy & Way, 1981).

Gastric Epithelial Cells :

Gastric epithelial cells lining the stomach are of the columnar type. They are filled with mucigenous granules and are responsible for the lubrication of contents. About a third of them regenerate by mitosis daily. They do not respond to acid secretagogues. (Rains & Ritchie, 1977).

Parietal (Oxyntic) Cells:

Parietal Oxyntic cells occur only in the body of the