Meniscal Allograft Transplantation (MAT)

Essay
Submitted for Partial Fulfillment of the Masters Degree
in Orthopaedic Surgery

Presented by
Amgad Mohammed Haleem Ahmed Amin
M.B.B.Ch.

Supervised by
Prof. Dr. Akram Azzam
Professor of Orthopaedic Surgery
Faculty of Medicine, Cairo University

Prof. Dr. Abdel Aziz El Sengergy
Professor of Orthopaedic Surgery
Faculty of Medicine, Cairo University

Dr. Ahmed Mahmoud Mohammed Atteyat Allah
Assistant Professor of Orthopaedic Surgery
Faculty of Medicine, Cairo University

Faculty of Medicine,
Cairo University
2005

ABSTRACT

الكـلـمات الـدالــة (باللغــة العربيــة):

في الماضي، كانت أهمية الغضروف الهلالي في الحفاظ على سلامة الوظائف الحيوية للركبة غير مُدركة الأبعاد، مما حدى بالكثيرين إلى إزالة الغضروف عند أي بادرة تلفٍ به، ولكن وُجد أن المرضى قد أصيبوا بتآكل وخشونة مبكرة بمفصل الركبة، ومن هنا كان التفكير في عملية زراعة الغضروف الهلالي للركبة أملاً في القضاء على الأعراض الناتجة عن عدم تواجده ولتأجيل الإصابة بخشونة الركبة.

ويهدف هذا البحث إلى دراسة زراعة الغضروف الهلالي للركبة بواسطة رقعة الغضروف الهلالـي الآدميـة، بمـا فـي ذلك دواعـي العمليـة، ووسـائل حفظ الرقعـة ، وقيـاس حجم الرقعـة قبل الجراحـة، والتقنيـات الجراحيـة المسـتخدمة فـي الـزرع، ورد فعـل الجهـاز المنـاعي لـدى المتلقـي، وتأهيل ما بعد الجراحة، ونتائج هذه العملية.

Keywords (in English):

The importance of the meniscus was poorly understood, and meniscal excision was performed as the primary treatment for meniscal injury. Yet, meniscectomy caused degenerative changes in the knee. Therefore meniscal transplantation was proposed for alleviation of symptoms in the short term and postponement of degenerative changes after meniscectomy in the long term.

The aim of this study is to highlight meniscal allograft transplantation, its indications, graft processing and preservation, immunology of meniscal transplants, pre-operative graft sizing, surgical techniques, post operative rehabilitation & results and of the procedure.

# ACKNOWLEDGEMENT

In the name of God -the most merciful- whom I praise day & night for His blessings which He has bestowed upon me.

To my late father, may his soul rest in peace. To my dearest mother, who bore the heavy burden. To my charming sister & brothers, & to my beloved wife and lovable daughter, the sunshine of my life.

I remain indebted to all my family members; grandmother, uncles, aunts, and in-laws, all of whom have been a great support to me throughout my life.

It is a great honour to express my sincere gratitude and appreciation to **Prof. Dr. Akram Hassan Azzam**, Professor of Orthopedic Surgery, Faculty of Medicine, Cairo University, in whom I mostly admire the sincere dedication to the tuition of his students. To him, I remain most grateful for his kind assistance, encouragement and continuous support.

I remain most grateful and thankful to **Prof. Dr. Abdel Aziz ElSingergy**, Professor of Orthopedic Surgery, Faculty of Medicine, Cairo University, to whom I am deeply indebted for his meticulous supervision, sincere guidance, valuable advice and strenuous efforts.

I wish to express my deep gratitude and sincere thanks to **Dr.Ahmed Mahmoud Mohammed Atteyyat Allah**, Assistant Professor of Orthopedic Surgery, Faculty of Medicine, Cairo University, for his valuable guidance, expert assistance and fruitful criticism.

A special thanks is due to the eminent professors; **Prof. Dr. Mohammed Kamel Gouda**, Professor of Orthopedic Surgery, Faculty of Medicine, Cairo University, and **Prof. Dr. Ezzat Kamel**, Professor of Orthopedic Surgery, Faculty of Medicine, Ain Shams University, for granting me the honour of being on the discussion panel of this study.

I also find myself obliged to thank all staff members of the Orthopedic Surgery Department, Faculty of Medicine, Cairo University. For each one of them has added to my knowledge and modest experience. They remain the glistening gems in the royal crown of science, which forever dazzle my eyes.

CONTENTS

List of Figures

List of Abbreviations

- ACL: Anterior Cruciate Ligamnet
- ̊ C: Degrees Celsius
- cm: centimetres
- CT: Computed Tomography
- DMSO: Dimethylsulphoxide
- GAGs: Glycosaminoglycans
- HIV: Human Immunodeficiency Virus
- HLA: Human Leukocytic Antigen
- HTLV: Human T-cell Lymphotropic Virus
- LCL: Lateral Collateral Ligament
- MAT: Meniscal Allograft Transplantation
- MCL: Medial Collateral Ligament
- MHC: Major Histocompatibility Complex
- mm: millimeters
- MRI: Magnetic Resonance Imaging
- PCL: Posterior Cruciate Ligament
- PCP: Peri-meniscal Capillary Plexus
- PCR: Polymerase Chain Reaction
- ROM: Range Of Motion
- RPR : Rapid Plasma Reagin

INTRODUCTION

The menisci have reached their highest level of development in humans. Their function is essential to the normal function of the knee joint, various functions have been attributed to the menisci, some of which are known or proved, others theorized **(Miller, 1998**).

The treatment of meniscal injuries has evolved over the last thirty years. Initially, the importance of the meniscus was poorly understood, and meniscal excision was routinely performed as the primary treatment for meniscal injury (**Lipscomb & Henderson, 1947)**. However, contemporary understanding of the natural history and biomechanical consequences of a meniscectomized knee has led to a commitment to meniscal preservation. Still, there is an existing population of patients who have undergone subtotal meniscectomy, and there continue to be instances in which meniscal preservation was not possible. In these cases, knee function was adversely affected, with disruption of important meniscal functions **(Insall, 2001)**.

Historically, the indications and surgical techniques for excision of torn menisci have been controversial, orthopaedic surgeons have advocated total excision of the torn meniscus, while others have proposed subtotal excision. Justification for total excision was often based on short-term, functional recovery criteria. When longer follow-up was studied, increasing degenerative changes were noted, especially if total meniscectomy was performed **(Johnson et al., 1974).**

After meniscectomy, the decrease in tibiofemoral contact area and the increase in joint contact pressures commonly lead to articular cartilage degeneration **(Ahmed & Burk, 1978, 1983)**. The risk for tibiofemoral arthritis after meniscectomy has been demonstrated in clinical studies (**Rockborn & Messner,2000; Noyes et al., 2004**)

It has been shown that a meniscectomy may initiate a series of degenerative changes that have been well documented in the literature. **(Fairbank**, **1948)** in his classic article, clearly documented the progression of arthritis in meniscectomy knees and described 3 stages of radiographic changes that consistently delineate the evolving disorder. Stage 1 is defined as the formation of an anteroposterior ridge projecting downwards from the margin of the femoral condyle over the meniscal site. Stage 2 consists of a generalized flattening of the marginal half of the femoral articular surface, on the side of the meniscectomy, whereas stage 3 consists of narrowing of the joint space on the side of the meniscectomy with occasional associated varus-valgus deformity of the knee **(Insall, 2001)**.

These changes were a result of the loss of the weight-bearing function of the meniscus, and therefore meniscectomy can no longer be considered an entirely harmless procedure **(Miller, 1998**).

That is why there has been increased emphasis on the repair of meniscal tears, including complex tears that extend into the central avascular zone (**Rubman et al., 1996, 1998)**

Numerous classifications of tears of the menisci have been proposed based on location or type of tear, etiology, and other factors. Whereas it is recognized that tears are more common when degenerative changes, cystic formations, or congenital anomalies are present, most of the commonly used classifications are according to the type of tear found at surgery. These are (1) longitudinal tears, (2) transverse and oblique tears, (3) combination of longitudinal and transverse tears, (4) tears associated with cystic menisci, and (5) tears associated with discoid menisci **(Miller, 1998)**.

The most common criteria for meniscal repair include a vertical longitudinal tear greater than 1 cm in length located within the vascular zone. Tears in the red-red (1-3 mm from the menisco-synovial junction) and red-white (3-5 mm from the menisco-synovial junction) zones have excellent healing potential. The tear also should be unstable and displaceable into the joint. In addition, the patient should be active and less than 40 years old. The knee should be either stable or will be stabilized with a ligamentous reconstruction simultaneously. Finally, the bucket handle portion and the remaining meniscal rim should be in good condition (**Miller, 1998**).

However, not all meniscal tears can be repaired, especially if considerable tissue damage has occurred. Transplantation of human menisci was thus proposed to restore some load-bearing meniscal function. (**Noyes et al., 2004**)

According to **Noyes & Barber Weston**, **(1995)** "Meniscus deficiency is the number one problem in orthopaedics today." To patients, meniscal deficiency due to a prior partial or total meniscectomy is a problem nearly always leading to pain, swelling, arthritic changes and limitation of activity. To physicians, meniscal deficiency is a problem because of the lack of suitable solutions for their patients. To industry, the sequelae of a meniscus-deficient knee within an employee translate into loss of productivity and increase in monetary expenditures for health care benefits. **(Insall, 2001)**

In an effort to restore normal knee anatomy and biomechanics, meniscal allografts are used to replace the native meniscus in selected symptomatic individuals **(Cole et al., 2002**).

The goals of meniscal transplantation are alleviation of symptoms in the short term and prevention or postponement of the appearance of degenerative changes after meniscectomy in the long term.

Intermediate-term reports indicate that excellent pain relief and improved function can be achieved when rigid indications are adhered to, and it is hoped that emerging long-term data will demonstrate a continued improvement compared with the meniscus-deficient knee **(Carter, 1997, 1999, 2000; Cole et al., 2002**).

Considering that meniscal transplantation is relatively new, it is too early to determine its long-term effect on the meniscus-deficient knee. Most of the reported series to date have been short term **(Rodeo et al., 2000; Stollsteimer et al., 2000)**. To determine the effectiveness of this investigational procedure, additional long-term functional and radiographic results should be provided. **(Rath et al., 2001)**

Aim of study:

The aim of this study is to highlight meniscal allograft transplantation (MAT), its indications, graft processing and preservation, immunology of meniscal transplants, graft biology and healing, pre-operative graft sizing, surgical techniques, post operative rehabilitation results and follow up of cases in literature.

BASIC SCIENCE OF THE MENISCI

Applied anatomy:

To understand meniscal pathology, it is important to know the basic embryological and vascular features of the meniscus. Both the lateral and medial menisci assume their characteristic shapes early in prenatal development. The meniscus is identifiable about seven and half weeks after ovulation **(Clarks & Ogden, 1983)**.

The semi-lunar cartilage gained its name from the C-shaped appearance reminiscent of the moon as the month begins. Arising from the tibia, the menisci serve to deepen the surface of the tibial plateau. The menisci are crescents roughly triangular in cross section, covering one half to two thirds of the articular surface of the corresponding tibial plateau. The outer rims of the menisci are convex and attached to the knee joint capsule. The inner edges are concave, thin and free **(Rath & Richmond, 2000)**. The proximal surfaces of the menisci are concave and are in contact with the femoral condyles; the distal surfaces are flat and rest on the tibial plateau. **(Insall, 2001)**

The **blood supply** of the menisci originates from the lateral and medial superior and inferior genicular arteries. These vessels reach the periphery of the meniscus through the synovial covering of the anterior and posterior horn attachments. Vessels are present throughout the substance of the fetal menisci. These blood vessels are most prominent in the peripheral 1/3 of the menisci and in the adjacent coronary and capsular ligaments (Fig. 1). Beginning at birth, there is a progressive decrease in vascularity proceeding from the inner to the outer regions of the meniscus, although at the age of ten, vessels can still be identified throughout the inner zones. The adult meniscus is avascular in the inner 2/3 **(Arnoczky & Warren, 1982; Clarks & Ogden, 1983)**.

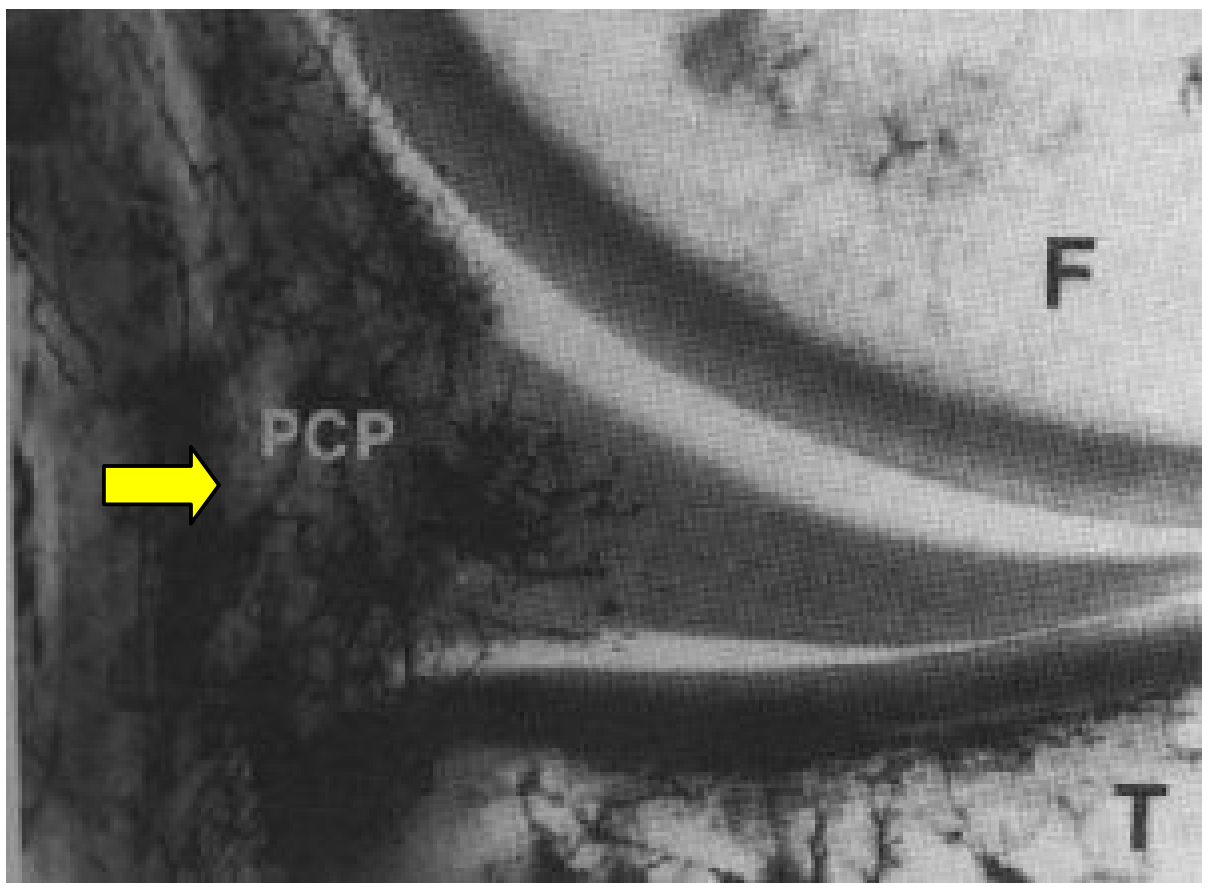

Fig. 1: Frontal section of the medial compartment: demonstrating the microvasculature of the medial meniscus. The peri-meniscal capillary plexus (PCP) (yellow arrow) permeates through the peripheral border of the meniscus.

(F: Femur, T: Tibia)

(Arnoczky & Warren, 1982)

The **medial meniscus** is C-shaped and occupies 50% of the articular contact area of the medial compartment (Fig. 2). It is nearly semicircular in form and about 3.5 cm in length. It has a triangular cross section and is asymmetric with a considerably wider posterior horn than anterior horn. It is firmly attached to the posterior intercondylar fossa of the tibia directly anterior to the PCL insertion. The anterior attachment is more variable; usually, it is firmly attached to the anterior intercondylar fossa, approximately 7 mm anterior to the anterior margin of the ACL insertion in line with medial tibial tubercle, but this attachment can be quite flimsy. There is also a fibrous band of variable thickness, the transverse intermeniscal ligament, that connects the anterior horn of the medial meniscus to the lateral meniscus **(Fig.2)**. Peripherally, the medial meniscus is continuously attached to & merges with the capsule of the knee. The midpoint of the medial meniscus is more firmly attached to the femur via a condensation in the capsule known as the deep medial ligament. The tibial attachment of the meniscus, sometimes known as the coronary ligament, attaches to the tibial margin a few millimeters distal to the articular surface, giving rise to a synovial recess. Posteromedially, the meniscus receives a portion of the insertion of the semimembranosus via the capsule **(Insall, 2001)**.

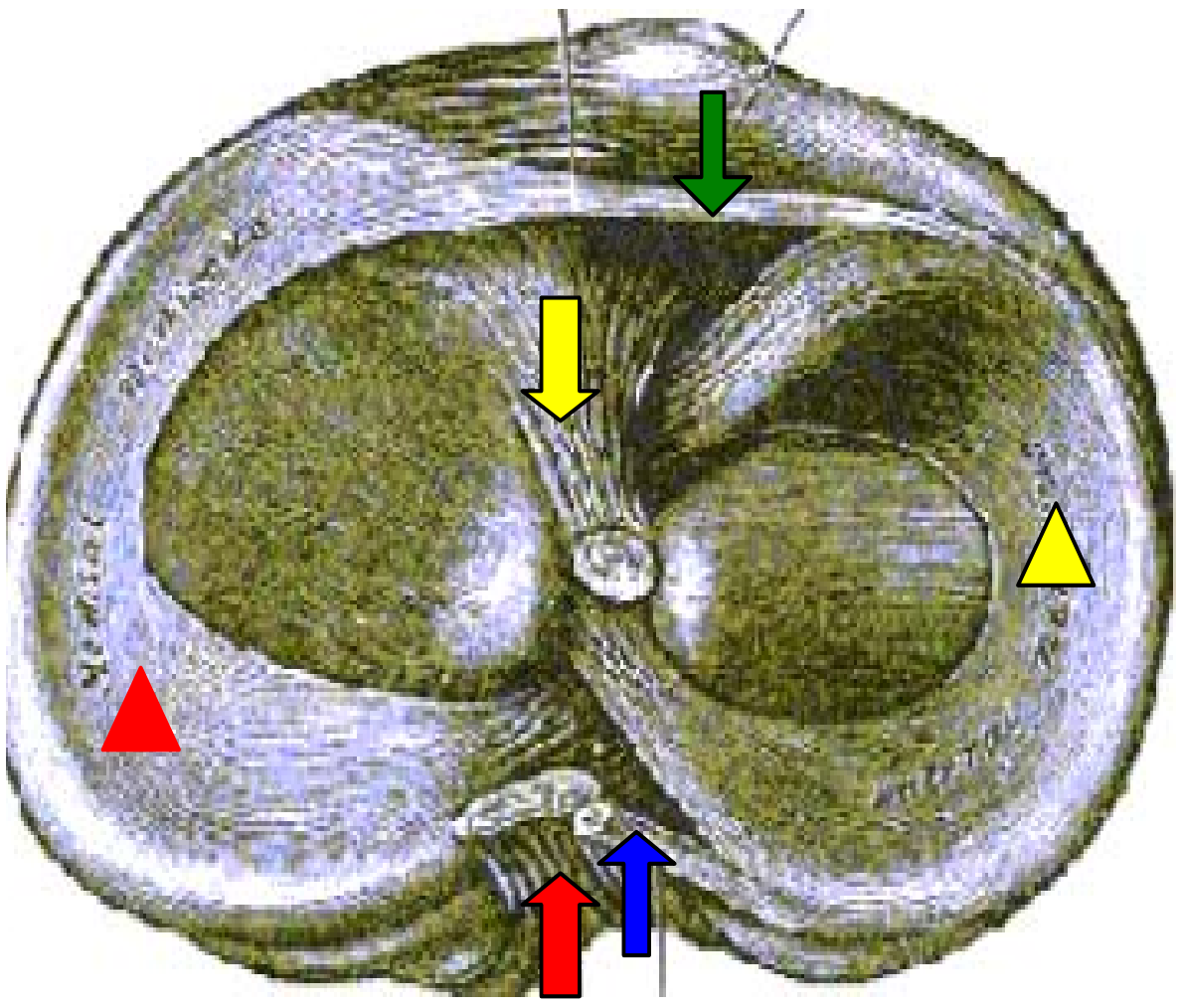

Fig. 2: Meniscal Anatomy
Posterior cruciate ligament (red arrow), anterior cruciate ligament (yellow arrow), transverse meniscal ligament (green arrow), ligament of Wrisberg (blue arrow), medial meniscus (red triangle), lateral meniscus (yellow triangle).
(Williams et al., 1993)

In distinction to the C-shaped medial meniscus, the **lateral meniscus** is nearly circular and covers a larger portion of the articular surface than the medial meniscus (70% of the lateral tibial plateau) **(Fig.2)**. The anterior horn is attached to the intercondylar fossa, directly anterior to the lateral tibial tubercle and adjacent to the ACL. The posterior horn is attached to the intercondylar fossa directly posterior to the lateral tibial tubercle and adjacent and anterior to the posterior horn of the medial meniscus. Somewhat variable fibrous bands, the