

2 K m D i k k

# Comparative Study of Different Treatment Modalities of Bacterial Endophthalmitis in Egypt

*Thesis*

*Submitted in Partial Fulfilment for  
M.D. Degree (Ophthalmology)*

6/4-7  
1. M. M.  
1350

*By*

**Mohamed Mostafa Kamel**  
*M.B.B.Ch., M.Sc. (Ophthalmology)*



*Supervised by*  
**Prof. Dr./ Negm El-Din Helal**

*Professor of Ophthalmology*  
*Faculty of Medicine – Ain Shams University*

**Prof. Dr./ Ahmed Samy Abu El Naga**


*Professor of Ophthalmology*  
*Faculty of Medicine – Ain Shams University*

**Prof. Dr./ Osama Abd El Monaem Raslan**

*Professor of Ophthalmology*  
*Faculty of Medicine – Ain Shams University*

*Faculty of Medicine*  
*Ain Shams University*

1999



توقيع لجنة المناقشة

م. د. نبلا ر علي القوي

فردی، تاک

ضمیمہ الدین ہلال (نمبر ۱۳۱، ۱۳۱۲ھ)



## ACKNOWLEDGEMENTS

I would like to express my deepest gratitude to ***Professor Dr. Negm El Din Helal***, Prof. of Ophthalmology, Faculty of Medicine, Ain Shams University, for the unlimited help, instruction and guidance which tough me so much and enabled me to present this study.

I would like to express my sincere appreciation to ***Professor Dr. Ahmed Samy Abu El Naga***, Prof. of Ophthalmology, Faculty of Medicine, Ain Shams University for his help and valuable contribution with processing, assembling and presentation of this work.

It is very great pleasure to acknowledge with appreciation ***Professor Dr. Osama Abd El Monaem Raslan***, Prof. of Ophthalmology, Faculty of Medicine, Ain Shams University who has borne much of the burden of this work. He has guided my foot steps and gave me from his time and supply valuable opinion with excellent supervision that helped me in the preparation of this study.

Thanks must also go to ***Professor Dr. Talat El Deeb***, Prof. of Pathology, Faculty of Medicine, Ain Shams University for his help and encouragement.



## CONTENTS

	Page
<b>INTRODUCTION</b> .....	<b>1</b>
<b>AIM OF THE WORK</b> .....	<b>3</b>
<b>REVIEW OF LITERATURE</b> .....	<b>4</b>
Definition .....	4
Classification .....	4
Incidence .....	9
Etiology .....	11
Clinical presentation .....	15
Differential Diagnosis .....	18
Treatment .....	20
- Antibiotic therapy .....	21
- Role of vitrectomy .....	30
Subsequent management .....	33
Prognosis .....	35
Anatomical facts about the rabbit's eye .....	37
<b>SUBJECTS AND METHODS</b> .....	<b>39</b>
The experimental work .....	39
Human patients .....	54
<b>RESULTS</b> .....	<b>63</b>
1) The experimental work .....	63
2) Human patients .....	108
<b>DISCUSSION</b> .....	<b>141</b>
The experimental work .....	141
Human patients .....	152
<b>CONCLUSION</b> .....	<b>162</b>
<b>SUMMARY</b> .....	<b>163</b>
<b>REFERENCES</b> .....	<b>167</b>
<b>ARABIC SUMMARY</b>	

## LIST OF TABLES

No.		Page
I	Doses of selected antimicrobials and other agents in endophthalmitis	23
II	Preparation of intravitreal antibiotics	24
1	Quantitative clinical grading scale	53
2	Inflammatory score of control group of rabbits in pretreatment period	66
3	Inflammatory score of control group of rabbits allover follow up period	68
4	Inflammatory score of intravitreal antibiotic group of rabbits in pretreatment period	70
5	Inflammatory score of intravitreal antibiotic group of rabbits allover follow up period	74
6	Inflammatory score of vitrectomy group of rabbits in pretreatment period	76
7	Inflammatory score of vitrectomy group of rabbits allover the follow up period	80
8	Inflammatory score of combined group of rabbits in pretreatment period	82
9	Inflammatory score of combined group of rabbits allover the period of observation	86
10	The inflammatory grading of rabbits in the different treatment modalities allover the follow up period	88
11	Percentage of rabbit's culture results that mere positive after treatment	92
12	Percentage of rabbit's eyes with opaque cornea after one and two weeks	94
13	Histopathological grading of experimental rabbit's eyes	98
14	Pre and posttreatment visual acuity of intravitreal and both group of humans	110
15	Grades of inflammatory scales of intravitreal antibiotic group of humans in pretreatment period	112
16	Inflammatory score of intravitreal antibiotic group of humans allover the period of observation	118
17	Inflammatory score of combined group of humans in pretreatment period	124
18	Pre and postoperative visual acuity of combined groups of humans	128
19	Inflammatory score of combined group of humans allover the period of observation	128
20	Inflammatory score of the vitrectomy group of humans in pretreatment period	132
21	Pre and postoperative visual acuity of sole vitrectomy group of humans	136
22	Inflammatory score of vitrectomy group of humans allover the period of observation	138
23	The inflammatory grading of humans in different treatment during the follow up period	140

## LIST OF GRAPHS

No.		Page
1	Inflammatory score of rabbits of control group	67
2	Inflammatory score of rabbits of intravitreal antibiotic group	73
3	Inflammatory score of rabbits of vitrectomy group	79
4	Inflammatory score of rabbits of combined group	85
5	Mean $\pm$ inflammatory score of rabbits in different treatment modalities	87
6	Percentage of culture results that were positive after treatment	91
7	Percentage of rabbit's eyes with opaque cornea after one week	95
8	Percentage of rabbit's eyes with opaque corneas after two weeks	97
9	Histopathological examination of experimental rabbit's eyes	99
10	Inflammatory score of the humans of intravitreal antibiotic group	117
11	Inflammatory score of the humans of the combined group	127
12	Inflammatory score of the humans of the vitrectomy group	137
13	Inflammatory scores of the humans in different treatment modalities	139



1

2

3

4

5

6

7

8

9

10

11

12

13

14

15

16

17

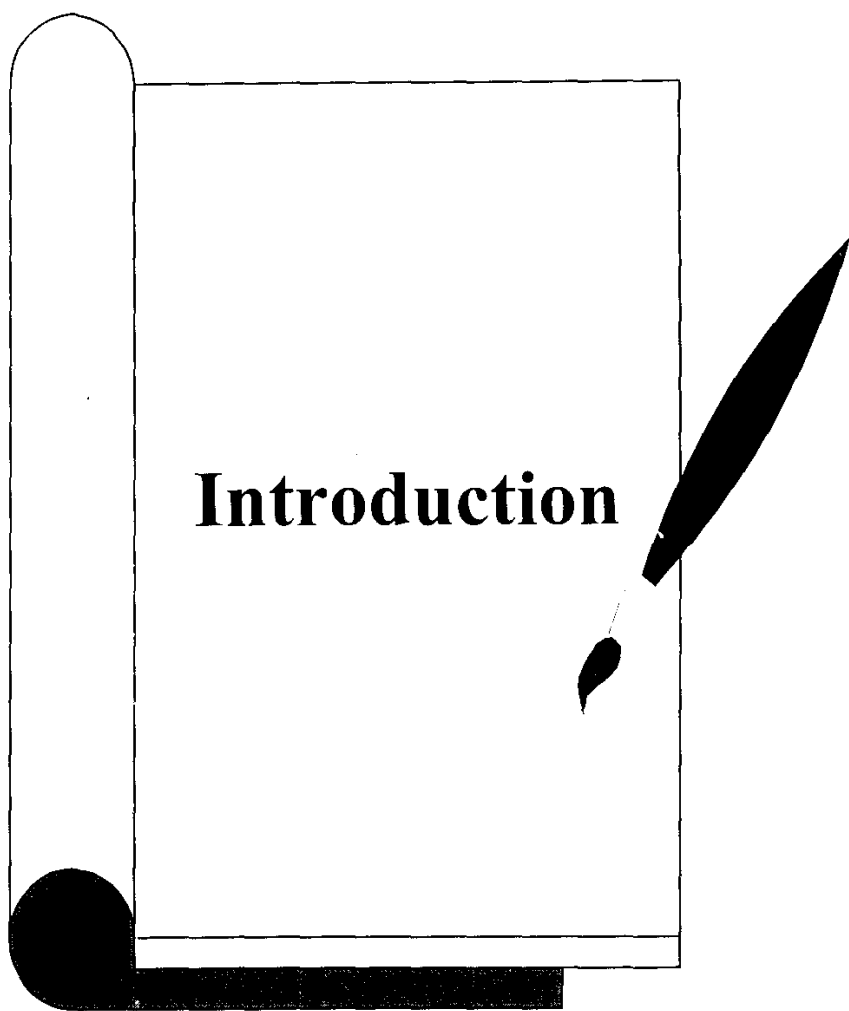
18

19

## LIST OF FIGURES

No.		Page
1	Ketamine hydrochloride used for general anesthesia of rabbits	42
2	Neutral slope agar and solution of staph. aureus bacteria	44
3	Intravitreal antibiotic drugs used in the study	46
4	A rabbit eye showing endophthalmitis	46
5	A sharp stiletto for the creation of the sclerotomies	48
6	Infusion canula in rabbit eye	48
7	Vitrectomy probe inside rabbit eye	50
8	Cutting and suction of vitreous by vitrectomy probe	50
9	A rabbit of control group in pretreatment period	65
10	The same rabbit of control group after two weeks	65
11	A rabbit of intravitreal antibiotic group in pretreatment period	71
12	The same rabbit of intravitreal antibiotic group after two weeks	71
13	A rabbit of the vitrectomy group in the pretreatment period	77
14	The same rabbit of the vitrectomy group after two weeks	77
15	A rabbit of the combined group in the pretreatment period	83
16	The same rabbit of the combined group after two weeks	83
17	Blood agar plate showing beta-hemolysis	89
18	Blood agar plate showing negative culture	89
19	A rabbit eye showing total corneal opacity	93
20	H & E section of a rabbit globe of intravitreal antibiotic group	100
21	H & E section of a rabbit globe of intravitreal antibiotic group	100
22	H & E section of a rabbit globe of vitrectomy group	101
23	H & E section of a rabbit globe of vitrectomy group	101
24	H & E section of the posterior segment of a rabbit of control group (x 40)	102
25	The same H & E section (x 250)	102
26	H & E section of the posterior segment of a rabbit of intravitreal antibiotic group (x 40)	103
27	The same H & E section (x 100)	103
28	H & E sector of the posterior segment of a rabbit of vitrectomy group (x 40)	104
29	The same H & E section (x 100)	104
30	H & E section of the posterior segment of a rabbit of combined group (x 40)	105
31	The same H & E section (x 250)	105
32	H & E section of the anterior segment of a rabbit of control group (x 40)	106
33	H & E section of the anterior segment of a rabbit of	106

34	H & E section of the anterior segment of a rabbit of vitrectomy group (x 40)	10
35	H & E section of the anterior segment of a rabbit of combined group (x 40)	107
36	Fundus view of a patient of intravitreal group in pretreatment period	109
37	Anterior segment of the same patient of intravitreal antibiotic group in pretreatment period	109
38	Fundus view of the same patient after one week	111
39	Fundus view of the same patient after two weeks	111
40	U/S of a case of intravitreal antibiotic group in pretreatment period	113
41	U/S of the same case after 3 days of management	113
42	A case of intravitreal antibiotic group in pretreatment period	115
43	The same case after one week	115
44	Anterior segment view of a case of combined group in pretreatment period	119
45	Fundus view of the same case in pretreatment period	119
46	Anterior segment of the same case after one week	121
47	Fundus view of the same case after one week	121
48	Anterior segment of the same case after two weeks	123
49	Fundus view of the same case after two weeks	123
50	A human case of combined group in pretreatment period	125
51	The same human case after two weeks	125
52	A case of sole vitrectomy group in pretreatment period	131
53	The same case after 3 days of management	131
54	Fundus view of a human case of vitrectomy group in pretreatment period	133
55	Fundus view of the same case after one week	133
56	Fundus view of the same case after two weeks	135
57	The anterior segment of the same case after two weeks	135





## **INTRODUCTION**

Endophthalmitis refers to the inflammatory response caused by the infected or injured intraocular tissues. Microbial endophthalmitis had gained increasing interest because it was the most severe and vision threatening type of catastrophic complications of intraocular surgery and penetrating ocular trauma despite recent advances in diagnosis and treatment.

Although newer antibiotic agents combat highly resistant organisms, numerous instances of fulminating infections that defy all therapeutic effort still occur.

The poor prognosis for eyes with endophthalmitis is a result of the action of two destructive forces. First, bacterial invasion with secretions of toxins capable of massive destruction, second the host defense mechanism involves the

build up of white cells which produce proteolytic enzymes capable of inflicting damage to the eyes.

The target area for microbial therapy in endophthalmitis is the vitreous cavity. Intravitreal therapy is the cornerstone of antimicrobial administration whereas the role of topical, subconjunctival and intravenous antibiotics is controversial.

Significant progress has been achieved in the management of endophthalmitis to sterilize the eye by the use of diagnostic vitreous sampling, the increasing use of intravitreal antibiotics and therapeutic vitrectomy. Which one is the best therapy, the indication of surgery and its proper timing still controversial. Vitrectomy as initial therapy has been employed by some surgeons especially in acute cases. Another group preserved vitrectomy only for advanced severe cases, while others advocated vitrectomy only when other treatment modalities had failed.