


**FORENSIC TOXICOLOGICAL STUDIES  
OF  
THIORIDAZINE**



Thesis

Presented in Partial Fulfilment of the Requirement for  
Master Degree in Forensic Medicine and Toxicology

By

**KHIALED MOHAMED SAFWAT EL SAYED**

( M. B., B.Ch. )  
Ain Shams University  
1988

Supervisors

52669

**Prof. Dr.**

**AHMED KAMEL MASHHOUR**

Prof. & Head of Forensic Medicine & Clinical  
Toxicology Dept.  
Faculty of Medicine  
Ain-Shams University

**Prof. Dr.**

**TALAAT MAHMOUD EL DEEB**

Prof. of Pathology  
Faculty of Medicine  
Ain-Shams University


**Prof. Dr.**

**HANAN HAMED MOSTAFA**

Assistant Prof. of Forensic Medicine &  
Clinical Toxicology Dept.  
Faculty of Medicine  
Ain-Shams University

Submitted to  
**Faculty of Medicine  
Ain Shams University**

**1996**







بسم الله الرحمن الرحيم

﴿ رب أوزعني أن أشكر نعمتك التي أنعمت عليّ

وعليّ والدي وأولادك وأن أعمل صالحاً ﴾ ترضاه

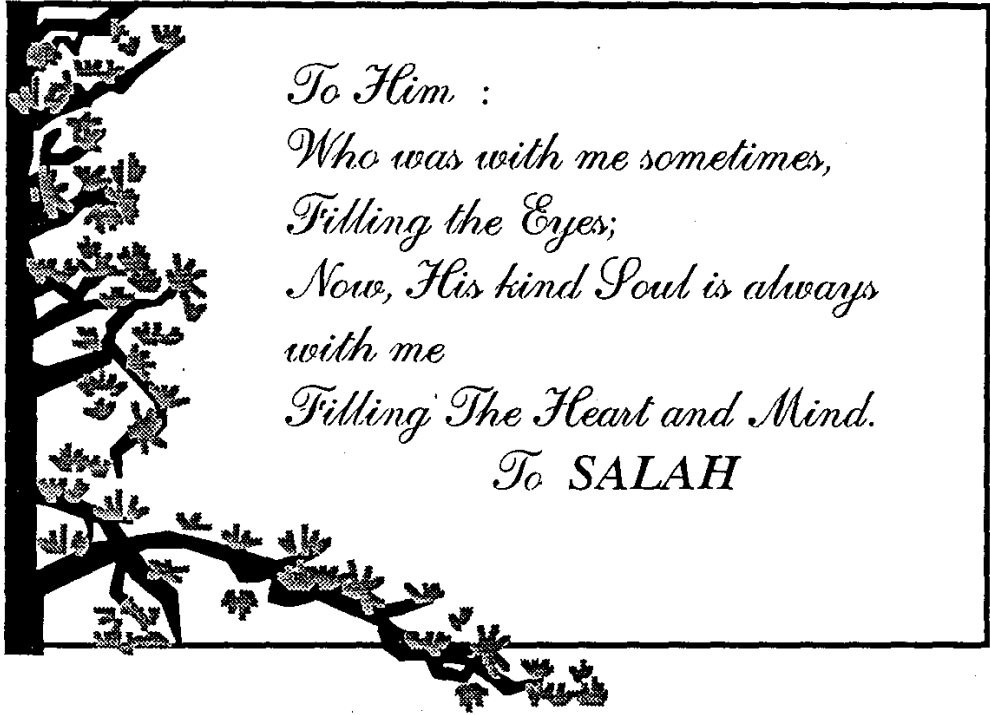
صدق الله العظيم  
آية ١٩ - سورة النمل

\* \* \* \* \*

" In the name of God-Most  
Gracious, Most Merciful "

" O my Lord, so order me that I may  
be grateful for Thy favours, which  
thou Hast bestowed on me and on my  
parents, and that I may work righ-  
teousness that will please thee ".







## Acknowledgement

*All thanks to ALLAH, the most helpful and most beneficent, who generously blessed me, through out my life.*

*My sincere gratitude, appreciation and respect are due to Professor Doctor Ahmed Kamel Mashhour, Professor and Head of forensic Medicine and Clinical Toxicology Department, Faculty of Medicine, Ain-Shams University for his limitless encouragement, overwhelming kindness, sincere help and continuous willing support. Words will never be enough to express my gratefulness to him.*

*I wish to express my thanks to Professor Doctor Talaat Mahmoud Et-Deeb, Professor of Pathology, Faculty of Medicine, Ain-Shams University, to whom I am greatly indebted for his professional help, willing support, and sincere supervision.*

*My deepest thanks and gratitude to Professor Doctor Hanan Hamed Mostafa, Assistant Professor of Forensic Medicine and Clinical Toxicology, Faculty of Medicine, Ain-Shams University, for her valuable guidance, constructive advice, close supervision, and encouragement.*

*I would like to express my special thanks and deepest gratitude to the eminent scientists : Professor Doctor Ali Mohamed Diab, Professor of Analytical Toxicology, Narcotic and Toxicology Lab. National Research Center; and Professor Doctor Somaya Hamouda, Undersecretary of Medicolegal Labs., Ministry of Justice, Egypt., for their constant encouragement, close supervision and for giving me the privilege of carrying this work under their professional*



*guidance, according to their modelling and invaluable practical experience. Their constructive guidance were the paramount axes in the selection, initiation and progress of this work.*

*Finally, a word of gratitude goes to my sincere Professors and staff of the Forensic Medicine and Clinical toxicology Department, Faculty of Medicine, Ain-Shams University for their encouragement to finish this work.*

*Khaled Mohamed Safwat*

## *CONTENTS*

	Page
- <i>Introduction and Aim of the Work</i> .....	1
- <i>Review of Literature</i> .....	3
- Physiological <sup>a</sup> bases of behaviour .....	3
- Development of Neuroleptics.....	6
- Phenothiazines.....	10
- Thioridazine .....	14
- Uses, Indications & Contraindications .....	22
- Toxicity and treatment.....	29
- <i>Methodology</i> .....	41
- <i>Res<sup>u</sup>lts and Discussion</i> .....	65
- <i>Summary</i> .....	139
- <i>Recommendations</i> .....	143
- <i>References</i> .....	147
- <i>Arabic Summary</i> .....	-



### *LIST OF TABLES*

Table No.		Page
1	Thioridazine/other phenothiazines Comparison	13
2	Extraction rate according to pH	51
3	TLC Eluent Systems	57
4	Body weight after long-term study	68
5	Results of colour tests	74
6	Colours obtained after spraying	77
7	Rf value of the drug	78
8	Thioridazine level after long term study	101
9	Biochemical changes after L.D.	113
10	Biochemical changes after long term study	117
11	Loss of the drug after putrefaction.	137



### *List of Figures*

Fig. No.		Page
1	The limbic System	4
2	Extrelut Column	50
3	Body weight in control group	69
4	Body weight after long term study	70
5	Total increase in body weight	71
6	Extraction rate / pH	72
7	TLC of the standard drug	79
8	TLC of the extracts from body organs	80
9	HPLC of the standard drug	82
10	Conc. of drug in the Brain after Lethal Dose (HPLC)	83
11	Conc. of drug in the Liver after L.D. (HPLC)	84
12	Conc. of drug in Kidney after L.D.(HPLC)	85
13	Drug level in Brain (Chronic)-(HPLC)	86
14	Drug level in Liver (chronic)- (HPIC)	87
15	Drug level in Kidney (chronic) (HPLC)	88
16	Drug level in hairs (chronic) (HPLC)	89
17	Drug level in control group	90
18	Calibration curve of the standard drug	91
19	Distribution of Thioridazine after L.D.	97
20	Conc. of the drug after L.D.	98
21	Distribution of drug after 2 weeks	99
22	Distribution of drug after 4 weeks	100
23	Conc. of Thioridazine after 2 weeks	102
24	Conc. of Thioridazine after 4 weeks	103
25	Distribution of Thioridazine after 6 weeks	104
26	Distribution of Thioridazine after 8 weeks	105
27	Conc. of Thioridazine after 6 weeks	106
28	Distribution of Thioridazine after 8 weeks.	107
29	Conc./duration of the drug in Serum	108
30	Conc./duration of Thioridazine in brain	109

### *List of Figures (Cont.)*

Figure No.		Page
31	Conc./duration of Thioridazine in liver	110
32	Conc./duration of Thioridazine in kidneys	111
33	Biochemical changes after L.D.	114
34	Biochemical changes after 8 weeks (SGPT)	115
35	Biochemical changes after 8 weeks (SGOT)	116
36	Biochemical changes after 8 weeks (creatinine)	118
37	Biochemical changes after 8 weeks (BUN)	119
38	Histopathological picture after L.D.(Brain)	122
39	Histopathological picture after L.D.(Liver)	123
40	Histopathological picture after L.D. (Kidney)	124
41	Histopathological picture after 4 weeks (Brain)	125
42	Histopathological picture after 4 weeks (Liver)	126
43	Histopathological picture after 4 weeks (Kidneys)	127
44	Histopathological picture after 6 & 8 weeks (Brain)	128
45	Histopathological picture after 6 weeks (Liver)	129
46	Histopathological picture after 8 weeks (Liver)	130
47	Histopathological picture after 6 weeks (Kidneys)	131
48	Histopathological picture after 8 weeks (Kidneys)	132
49-51	Histopathological picture of organs in controls	133-135