



شبكة المعلومات الجامعية

بِسْمِ اللَّهِ الرَّحْمَنِ الرَّحِيمِ





شبكة المعلومات الجامعية



# شبكة المعلومات الجامعية

## التوثيق الالكتروني والميكرو فيلم

# جامعة عين شمس

التوثيق الالكتروني والميكرو فيلم

## قسم

نقسم بالله العظيم أن المادة التي تم توثيقها وتسجيلها  
علي هذه الأفلام قد اعدت دون أية تغيرات



## يجب أن

تحفظ هذه الأفلام بعيداً عن الغبار

في درجة حرارة من 15 – 20 مئوية ورطوبة نسبية من 20-40 %

To be kept away from dust in dry cool place of  
15 – 25c and relative humidity 20-40 %



شبكة المعلومات الجامعية



# بعض الوثائق الأصلية تالفة



شبكة المعلومات الجامعية



بالرسالة صفحات  
لم ترد بالأصل



**INCIDENCE & MANAGEMENT  
OF AFTER-CATARACT  
AT SOHAG UNIVERSITY HOSPITAL**

*Thesis*  
**Submitted In Partial Fulfillment  
for  
M. D. Degree In Ophthalmology**

*By*  
**ALI MAHMOUD ISMAIL**  
**Assistant Lecturer Of Ophthalmology**  
*Sohag Faculty Of Medicine*  
*South Valley University*

*Supervised by*


*Prof. Dr. Kamel Abd-Elnaser*  
**Professor & Head Of**  
**Ophthalmology Department**  
*Asuit University*

*Dr. Ismail Mosa*  
**Assistant Prof. O**  
**Ophthalmology**  
*Sohag Faculty Of Medi*  
*South Valley Univers*

*South Valley University*

**1998**

*B.A.V.E.V*




# CONTENTS

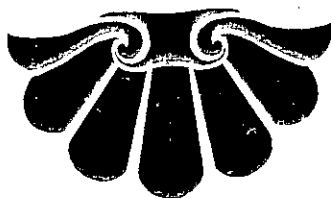
• Acknowledgment	1
• Introduction	2
• Aim of the work	4
• Review	5
1-Incidence of after-cataract	5
2-Etiology, Pathogenesis and Pathology of after - cataract	9
3-After -cataract & Visual impairment	15
4-Types of after-cataract	16
5-Forms of after-cataract	17
6-Assessment of after-cataract	21
7-Prevention of after-cataract	24
8-Management of after-cataract	30
11-Membranectomy & posterior capsulotomy technique in pseudophakic eye	52
12-Effectiveness of YAG laser treatment of after- cataract	56
13-Complications of Nd: YAG laser capsulotomy	59
14-Results of Nd: Nd: YAG laser capsulotomy	64
• Material & methods	66
• Results	88
• Discussion	124
• Summary & conclusion	140
• References	145
• Arabic summary	







# ACKNOWLEDGMENTS





## ACKNOWLEDGMENTS

*I wish to express my extreme gratitude to **Prof. Dr. Kamel Abdel-Naser**, professor of ophthalmology , head of the department , Assiut University , for his valuable advice while conducting this work .*

*I would like to express my sincere appreciation to **Dr. Ismail Mosa** assistant professor of ophthalmology , Sohag University Hospital for his faithful supervision , his continuous help encouragement and cooperation throughout this work.*

*I'm greatly indebted to **Dr. Gamal Abd-Latif** assistant professor of ophthalmology , head of the department Sohag University Hospital for his kind guidance and constant support .*

Ali Mahmoud Ismail





# INTRODUCTION & AIM OF THE WORK

