

A Comparative Study between the Use of Endoscopic Assisted Versus Other Methods in Repair of Subcondylar Fracture Mandible

Thesis

Submitted for Partial Fulfillment of MD Degree
in Plastic Surgery

Presented By

Sarah Abd-alazeem Abd-almaksoud Farrag

M.B.B.Ch., M.S. in General Surgery
Ain Shams University

Under the Supervision of

Professor/ Ikram Ibrahim Safe

Professor of Plastic & Reconstructive Surgery
Faculty of Medicine, Ain Shams University

Professor/ Karim Samir Massoud

Professor of Plastic & Reconstructive Surgery
Faculty of Medicine, Ain Shams University

Assistant Professor/ Amir Samir Elbarbary

Assistant Professor of Plastic & Reconstructive Surgery
Faculty of Medicine, Ain Shams University

Faculty of Medicine
Ain Shams University

2013

بِسْمِ اللَّهِ الرَّحْمَنِ الرَّحِيمِ

رَبِّ أَوْزَعْنِي أَنْ أَشْكُرَ نِعْمَتَكَ
الَّتِي أَنْعَمْتَ عَلَيَّ وَعَلَى وَالِدَيَّ
وَأَنْ أَعْمَلَ صَالِحًا تَرْضَاهُ وَأُوْخِذَنِي
بِرَحْمَتِكَ فِي عِبَادِكَ الصَّالِحِينَ

صدق الله العظيم

سورة النمل آية (١٩)

Acknowledgments

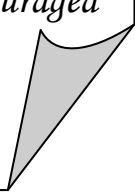
First and last, I thank "Almighty Allah" as I owe HIM mercy, support and guidance throughout my life.

*I would like to express my deepest appreciation to **Prof. Dr. Ikram Safe**, Professor of Plastic and Reconstructive Surgery, Ain Shams University, for giving me the honor of working under his supervision and providing me a lot of encouragement throughout this work.*

*I wish to express my everlasting debt for the effort and help provided by **Prof. Dr. Karim Masood**, Professor of Plastic and Reconstructive Surgery, Faculty of Medicine, Ain Shams University, who saved no time or effort helping me with this work.*

*My deepest appreciation and grateful thanks are for **Dr. Amir Elbarbary**, Assistant Professor of Plastic and Reconstructive Surgery, Faculty of Medicine, Ain Shams University, who saved no time or effort helping me with this work.*

Last but not least, I would like to record thanks to my family, friends, and all those who have helped and encouraged me in the production of this work.



List of Contents

Subject	Page
List of Abbreviations	I
List of Tables	II
List of Figures	VI
Introduction	1
Aim of the Work	4
Review of Literature	
Chapter (1): Endoscopy: History, Equipment, Instrumentation, Setup, and Troubleshooting	5
Chapter (2): Anatomy of the Tempromandibular Region	22
Chapter (3): Diagnosis and Decision Making in Subcondylar Fractures of the Mandible	56
Chapter (4): Surgical approaches to the Tempromandibular Region	74
Chapter (5): Surgical Technique of EAORIF of Subcondylar Fractures of the Mandible	96
Patients and Methods	115
Results	126
Discussion	142
Summary and Conclusion	152
References	155
Arabic Summary	\

List of Abbreviations

Abb.	Meaning
ATLS	Advanced Trauma Life Support
EAORIF	Endoscopic Assisted Open Reduction and Internal Fixation
MIP	Maximal Intercuspal Position
MMF	Maxillomandibular Fixation
ORIF	Open Reduction and Internal Fixation
RM	Retromandiblar
SMAS	Superficial Musculoaponeurotic System
TMJ	Tempromandibular Joint
VCR	Videocassette Recorder

List of Tables

Table No.	Title	Page
Table (2-1)	Summarizing the location, principal morphological and behavioural characteristics of the four varieties of articular receptor nerve ending	44
Table (3-1)	Physical Examination Findings	60
Table (3-2)	The Lindahl System of Classification	64
Table (3-3)	and Kent's Metamorphosis of the Indications for Open Reduction	67
Table (3-4)	Contraindications for Endoscopic Reduction and Rigid Fixation of Mandibular Condyle Fractures	73
Table (7-1)	Comparison between both studied groups as regard age and gender showing no statistically significant difference between the both studied groups	126
Table (7-2)	Distribution of the studied cases in regard to type of trauma showing no statistically significant difference between both groups using chi-square test	127
Table (7-3)	Comparison between both studied groups as regards the site of the fracture showing no statistically significant difference between both studied groups using chi-square test	128

Table No.	Title	Page
Table (7-4)	Comparison between both studied groups in regard to range of mouth opening showing no statistically significant difference between both studied groups using unpaired t-test	129
Table (7-5)	Comparison between both studied groups regarding preoperative clinical findings showing no statistically significant difference between both studied groups using chi-square test	130
Table (7-6)	Comparison between both groups as regard radiological findings showing no statistically significant difference between both group by using chi-square test	130
Table (7-7)	Comparison between preoperative versus postoperative regarding range of mouth opening among both groups showing statistically significant difference using paired t-test. The percent of change was higher in group I	131
Table (7-5)	Comparison between preoperative versus immediate postoperative symptoms among group I showing statistically significant occlusal improvement using chi-square test. Pain, clicking, and deviation were not assessed since the mouth was closed in MMF group	132

Table No.	Title	Page
Table (7-9)	Comparison between preoperative versus immediate postoperative symptoms among group II showing statistically significant improvement as regard clicking, occlusion, and deviation using chi-square test. There was no statistically significant difference as regard pain	133
Table (7-10)	Comparison between preoperative versus late postoperative clinical findings among group I showing statistically significant improvement regarding occlusion, and deviation using chi-square test. On the other hand there was no significant difference as regard pain and clicking	135
Table (7-11)	Comparison between preoperative versus late postoperative clinical findings among group II showing statistically significant improvement as regard all parameters using chi-square test	135
Table (7-12)	Changes in preoperative and postoperative radiological findings among both groups showing statistically significant improvement in group II using Mc Nemar's test. on the other hand there is no significant difference in group I	136

Table No.	Title	Page
Table (7-13)	Comparison between both studied groups regarding immediate postoperative symptoms showing no statistically significant difference between both groups using chi-square test	137
Table (7-14)	Comparison between both studied groups as regard late postoperative findings showing no statistically significant difference between both groups by using chi-square test	140
Table (7-15)	Comparison between both groups as regard radiological findings showing statistically significant improvement in group II as regards immediate and late postoperative panorama, and immediate postoperative CT using chi-square test	141

List of Figures

Figure No.	Title	Page
Figure (1-1)	The Hopkins rod endoscope is essentially a glass rod with interspersed air spaces as opposed to a conventional scope, which is a tube of air with interspersed glass lense	7
Figure (1-2)	The basic endoscopic equipment consists of endoscope, camera, light source, and monitor	9
Figure (1-3)	Schematic of the rigid endoscope showing the optic fibers surrounding the lens chain. As the diameter of the scope gets smaller, the room for the optic fibers decreases so that the amount of light one is able o get into the wound also decreases. As the diameter gets smaller the actual amount of light the lens is able to collect also decreases geometrically	10
Figure (1-4)	The essential assemblage is to join the camera, coupler, endoscope, and light source. Endoscope system consisting of camera (CA). coupler (CO), endoscope (EN), and light source (LS)	11
Figure (1-5)	Arrangement of the surgeon, assistant, and endoscopic video monitor in relation to a fracture	15
Figure (2-1)	Devison of the frst branchial arch into maxillary and mandibular processes.	23

Figure No.	Title	Page
Figure (2-2)	Human embryo (29 mm C-R; week 8 of Development). Frontal section of the posterior joint region	24
Figure (2-3)	Schematic drawing of the condylar cartilage (CC) during week 10 of development	25
Figure (2-4)	Schematic drawing of the arrangement in the posterior joint region of the articular capsule	26
Figure (2-5)	The mandible has a horseshoe shape. The figure shows the lateral and medial surfaces of the ramus	28
Figure (2-6)	The mandibular condyle can be divided into the condylar (intracapsular) and subcondylar (extracapsular) regions	29
Figure (2-7)	Showing the bony components of the TMJ	32
Figure (2-8)	The posterior group of muscles attached to the mandible	34
Figure (2-9)	The tempromandibular joint and its associated ligaments	37
Figure (2-10)	The temporomandibular joint (TMJ) capsule and lateral ligament	40
Figure (2-11)	Sagital section through the temporomandibular joint (TMJ)	40
Figure (2-12)	Branches of the auriculotemporal nerve supply sensory innervation of the TMJ	42
Figure (2-13)	Illustration showing the plan of branches of internal maxillary artery, and beginning of superficial temporal artery	46

Figure No.	Title	Page
Figure (2-14)	Branches of the facial nerve	50
Figure (2-15)	Coronal section of the temporomandibular joint (TMJ) region	53
Figure (2-16)	The buccal fat pad and its extensions	55
Figure (3-1)	Sites of weakness of the mandible	56
Figure (3-2)	Direct or indirect trauma to the TMJ causing injury to surrounding structures	58
Figure (3-3)	Condylar fractures classification	64
Figure (3-4)	CT reconstructions of a patient showing medial and lateral override	71
Figure (4-1)	Subperiosteal dissection of the ramus in the intraoral approach	75
Figure (4-2)	Relationship of the facial artery and vein, the marginal mandibular branch of the facial nerve	79
Figure (4-3)	Incision through the pterygomasseteric sling after retraction of vital structures	81
Figure (4-4)	Exposure offered by the submandibular approach	82
Figure (4-5)	Incision marked for the RM approach	85
Figure (4-6)	Exposure offered by the retromandibular approach: transparotid and retroparotid	85
Figure (4-7)	Exposure offered by the rhytidectomy approach	86
Figure (4-8)	Outline for the modified endaural approach to the condyle	88

Figure No.	Title	Page
Figure (4-9)	Exposure offered by the preauricular approach	91
Figure (4-10)	Bicoronal approach	94
Figure (5-1)	Some of the instruments in the prototype endoscopic subcondylar fracture fixation set	97
Figure (5-2)	Endoscopic forehead lift retractor used in these procedures	97
Figure (5-3)	Methods of applying inferior traction to the ramus	102
Figure (5-4)	Placing a wedge in the posterior occlusion with anterior MMF	103
Figure (5-5)	Curved elevator developed for the retrieval of dislocated condylar fragments	105
Figure (5-6)	Endoscopic view of a left subcondylar fracture near the completion of fixation with 2 plates	107
Figure (5-7)	Intraoperative view of angulated drill	107
Figure (5-8)	Introducer designed to hold a zygomatic plate.	108
Figure (5-9)	Threaded fragment manipulator	109
Figure (5-10)	Summarization of EAORIF	110
Figure (5-11)	Three kinds of plates designed for stabilization of subcondylar fractures	112
Figure (6-1)	The blunt dissector passing through the (≤ 1 cm) submandibular incision	118

Figure No.	Title	Page
Figure (6-2)	A photograph showing downward traction applied by the interossious wire that is passing through the angle of the mandible	118
Figure (6-3)	A photograph showing the rigid , 4 mm, 30° endoscope	119
Figure (6-4)	A photograph showing the monitor, light source, and camera body (from above downwards).	119
Figure (6-5)	A photograph showing the camera head with its cable	119
Figure (6-6)	A photograph showing the light source cable	120
Figure (6-7)	A photograph showing different types of sheath retractors	120
Figure (6-8)	A photograph showing the miniplate applied to the proximal segment with one screw being applied	122
Figure (6-9)	A photograph showing the second drill hole application to the distal segment	122
Figure (6-10)	A photograph showing application of the remaining screws	122
Figure (7-1)	A graph showing increased range of mouth opening in both groups. The percentage of change is higher in group I	131

Figure No.	Title	Page
Figure (7-2)	Showing improvement in occlusion in group I and group II	132
Figure (7-3)	CT scans showing radiological changes in both groups.	137
Figure (7-4)	panoramic radiographs showing radiological changes in both groups.	138
Figure (7-5)	A graph showing the improvement in radiological findings in group II	141