



بسم الله الرحمن الرحيم



شبكة المعلومات الجامعية التوثيق الالكتروني والميكروفيلم



شبكة المعلومات الجامعية

جامعة عين شمس

التوثيق الالكتروني والميكرو فيلم

قسم

نقسم بالله العظيم أن المادة التي تم توثيقها وتسجيلها
على هذه الأفلام قد أعدت دون أية تغييرات



يجب أن

تحفظ هذه الأفلام بعيدا عن الغبار

في درجة حرارة من ١٥-٢٥ مئوية ورطوبة نسبية من ٢٠-٤٠%

To be Kept away from Dust in Dry Cool place of
15-25- c and relative humidity 20-40%

بعض الوثائق الأصلية تالفة

بالرسالة صفحات لم ترد بالاصل

ULTRASONOGRAPHIC MEASUREMENTS OF THE AMNIOTIC FLUID INDEX IN POSTTERM PREGNANCY

THESIS

*Submitted for Partial Fulfillment of Master Degree
In Obstetrics and Gynecology*

By

MOHAMED FARAG MOHAMED
(M.B.B.Ch.)

Supervisors

PROF. DR. MOHSEN KHAIRY AHMED

Professor of Gynecology and Obstetrics
Benha Faculty of Medicine
Zagazig University

DR. MOHAMED RAFIK GOHAR

Ass. Professor of Gynecology and Obstetrics
Benha Faculty of Medicine
Zagazig University

DR. MOHAMED KAMEL ALOUSH

Ass. Professor of Gynecology and Obstetrics
Benha Faculty of Medicine
Zagazig University

**BENHA FACULTY OF MEDICINE
ZAGAZIG UNIVERSITY**

1998



ULTRASONOGRAPHIC MEASUREMENTS OF THE AMNIOTIC FLUID INDEX IN POSTTERM PREGNANCY

THESIS

*Submitted for Partial Fulfillment of Master Degree
In Obstetrics and Gynecology*

By

MOHAMED FARAG MOHAMED
(M.B.B.Ch.)

Supervisors

PROF. DR. MOHSEN KHAIRY AHMED

Professor of Gynecology and Obstetrics
Benha Faculty of Medicine
Zagazig University

DR. MOHAMED RAFIK GOHAR

Ass. Professor of Gynecology and Obstetrics
Benha Faculty of Medicine
Zagazig University

DR. MOHAMED KAMEL ALOUSH

Ass. Professor of Gynecology and Obstetrics
Benha Faculty of Medicine
Zagazig University

**BENHA FACULTY OF MEDICINE
ZAGAZIG UNIVERSITY**

1998





بِسْمِ اللَّهِ الرَّحْمَنِ الرَّحِيمِ






Acknowledgments

Thanks first and last to God as we owe him for his great care, support, and guidance in every step in our life.


Special acknowledgment is given to Prof. Dr. Mohsen Khairy, Professor of Obstetrics and Gynecology, Benha Faculty of Medicine, for his unfailing advice and generous help. His gifted talent and witty hints smoothed a lot of the material, that otherwise seemed tough and unpalatable.

Indeed, words do fail me when I come to express my sincere indebtedness to Dr. Mohamed Gohar Assistant Professor of Obstetrics and Gynecology, Benha Faculty of Medicine, for his extraordinary honest effort and help. I was much impressed by his noble character, patience, and sympathy.

I wish also to express my deepest thanks to Dr. Mohamed Aloush, Assistant Professor of Obstetrics and Gynecology, Benha Faculty of Medicine, for his generous cooperation and constructive supervision during the practical work.

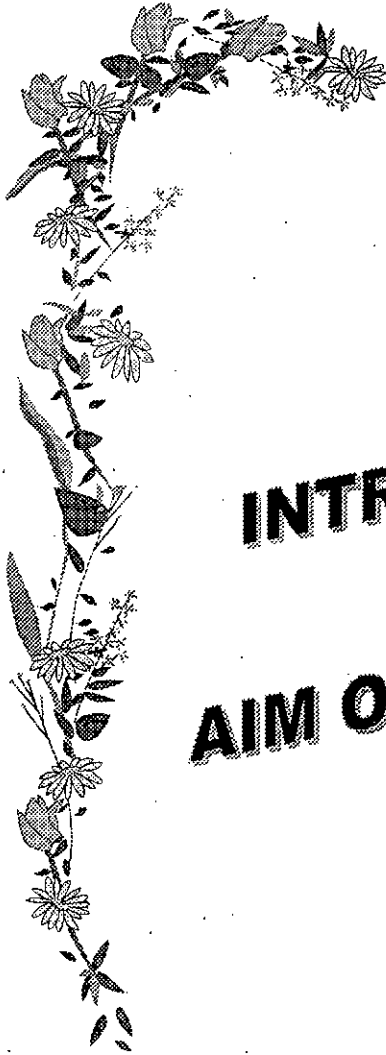

*To Whom Who Give Me
Love and Kindness
To My Parents*



CONTENTS

	Page
❖ <i>INTRODUCTION</i>	1
❖ <i>AIM OF THE WORK</i>	4
❖ <i>REVIEW OF LITERATURE</i>	5
- Postterm pregnancy	5
- Amniotic fluid	30
❖ <i>SUBJECTS AND METHODS</i>	46
❖ <i>RESULTS</i>	51
❖ <i>DISCUSSION</i>	61
❖ <i>SUMMARY</i>	66
❖ <i>REFERENCES</i>	68
❖ <i>ARABIC SUMMARY</i>	



INTRODUCTION AND AIM OF THE WORK



INTRODUCTION

Several investigators have demonstrated that prolongation of pregnancy beyond term is accompanied by a rise in perinatal morbidity and mortality (*Ariel et al., 1992; Michael et al., 1995 and Cunningham et al., 1997*).

Oligohydramnios has particular relevance to postterm pregnancies because the volume of amniotic fluid diminishes as gestation advances beyond term, therefore, ultrasonographic evaluation for the presence of oligohydramnios is extensively used for fetal testing in these pregnancies (*Michael et al., 1995*). Oligohydramnios in postterm pregnancies is associated with fetal heart rate decelerations and fetal asphyxia. A common belief is that the fetus with oligohydramnios is suffering from uteroplacental insufficiency, requiring it to preferentially shunt blood flow away from non-essential organs such as the kidneys. With less renal blood flow there would be decreased urine output and less amniotic fluid. This same mechanism is also assumed to cause a fetus to show other signs of distress (*Jodi et al., 1996*).

Numerous studies have shown that amniotic fluid volume assessment is critical in the evaluation of postterm gestation. *Crowley (1980)* found that the incidence of meconium stained liquor, fetal acidosis, cesarean section for fetal distress and low Apgar score were increased in postterm pregnancies complicated by decreased amniotic fluid volume.

Phelan (1987) found that adequate amniotic fluid volume in postterm pregnancies is a reliable predictor of fetal well-being and found a statistically increased incidence of cesarean section for fetal distress and passage of meconium in cases of decreased amniotic fluid volume. Amniotic fluid volume has been an effective method in predicting fetal distress in postterm pregnancy and has been significantly more accurate in predicting intrapartum fetal distress than non-stress test (*Tangsong and Srisomboon, 1993*).

Before the advent of ultrasound technology, amniotic fluid volume was usually estimated using indicator (dye) dilution techniques. These methods require amniocentesis to instill and recover the indicator and therefore have restricted clinical utility (*Ariel et al., 1992*). Real-time ultrasound allows non-invasive, semiquantitative amniotic fluid measurements to be conveniently made over a broad range of gestational ages. Ultrasonographic measurements of amniotic fluid volume are frequently expressed as a one dimensional linear distance of the largest pocket of amniotic fluid or a summation of these measurements over four uterine quadrants referred to as the amniotic fluid index (*Ariel and Michael, 1992 and Porter et al., 1996*).

Amniotic fluid index measurement may be a more appropriate mean than measurement of the single largest pocket or subjective assessment (*T. Moore, 1990*).

Amniotic fluid index value less than or equal to 5cm represents oligohydramnios. Amniotic fluid index value more than or equal to 20cm constitutes polyhydramnios (*Brace and Wolf, 1989*). Several sonographic studies have recently reported a weekly decrease in the amniotic fluid