

# **Management of Lisfranc Joint injury**

*Essay*

*Submitted for fulfillment of master degree in  
Orthopedic surgery*

*By: Sameh Adel Quorani Ali  
(MB, B.ch.)*

*Under supervision of:*

***Prof. Dr.: Ahmed Mahmoud Kholief***  
*Professor of orthopedic surgery  
Faculty of medicine  
Cairos Univ.*

***Dr.: Mostafa Mahmoud Ahmed***  
*Lecturer of orthopedic surgery  
Faculty of medicine  
Cairo Univ.*

Faculty of medicine  
Cairo Univ.  
2012

# **Contents**

1)	Introduction.....	1
2)	Aim of the work.....	2
3)	Anatomy.....	3
4)	Mechanism of injury.....	14
5)	Diagnosis.....	18
6)	Classification.....	26
7)	Treatment.....	33
8)	Complications.....	43
9)	Summary.....	60
10)	References.....	61
11)	Arabic Summary.	

## Acknowledgement

I would like to thank **ALLAH** a lot for his kindness, patience and strength he gave me to achieve this work and made me able to finish it.

I'm extremely grateful to **Professor Dr/ Ahmed Mahmoud Kholief** Professor of orthopedic surgery, Faculty of Medicine, Cairo University for his meticulous supervision, his valuable comments and his kind support. I greatly appreciate his efforts to guide me to accomplish this work properly so to him I express my deepest gratitude.

My special thanks to **Dr/ Mostafa Mahmoud Ahmed**, Lecturer of orthopedic surgery, Faculty of medicine, Cairo University, for his encouragement and revision of this work; he gave me much of his time.

A special dedication to **my family** for their never ending care. They were always supporting me and encouraging me to continue and to be successful especially my little children **Habiba & Omar** the best gift that God gave me.

## **Abstract**

. Generally, anatomic reduction and stabilization are essential for achieving a satisfactory outcome. Precise restoration of the congruity and functional relationship involving the respective metatarsals and adjoining lesser tarsus is paramount. Much of the recent literature suggests ORIF as the standard of care. Ensuring anatomic reduction and appropriate postoperative management will optimize clinical outcomes. However, be aware that, in certain cases, posttraumatic squeal may be inevitable even with timely and accurate anatomic reduction. Restoring alignment via an appropriate arthrodesis may be required for cases which are initially neglected, develop significant arthrosis or remain symptomatic in spite of appropriate care.

## **Key word**

Lisfranc- Joint injury- *Orthopedic*- Mechanism of injury

## **LIST OF FIGURES**

<b>Figures</b>	<b>Pages</b>
Fig.1: Foot bones.....	3
Fig.2: Lisfranc's complex.....	4
Fig.3: Roman arch.....	5
Fig.4: Lisfranc's ligament.....	7
Fig.5: Interosseous ligaments.....	8
Fig.6: The plantar fascia of foot.....	9
Fig.7: The dorsalis pedis artery.....	11
Fig.8: Intrinsic muscles of foot.....	12
Fig.9: Extrinsic muscles of foot.....	13
Fig.10: Indirect injury.....	16
Fig.11: Direct injury.....	17
Fig.12: 3CD image show homolateral in TMT joints.....	22
Fig.13: normal x-rays of TMT joints.....	23
Fig.14: Fleck sign.....	24
Fig.15:TMT Fracture dislocation.....	25
Fig.16: Quenu and kuss classification.....	27
Fig.17: Hardcastle classification.....	29
Fig.18: Myerson classification.....	31

Fig.19: Plate fixation of the cuboid was used to establish lateral column length and fixation of distal fracture.....	38
Fig.20: A Fluoroscopic image demonstrating placement of cannulated screw guide wires over the first and second tarsometatarsal joints.....	38
Fig.20: B.The middle column is reduced to the stabilized medial column with bone-reduction clamp.....	38
Fig.20: C. Fixation was obtained with use of screws.....	39
Fig.21: Closed Reduction and precutaneous pinning.....	40
Fig.22: This patient with first tarsometatarsal and naviculocuneiform joint osteoarthritis had pes planovalgus and forefoot abduction deformity with 5-year history of midfoot pain. The patient was treated with first tarsometatarsal and naviculocuneiform joint realignment and fusion with medial sliding calcaneal osteotomy and precutaneous Achilles tendon lengthening. Radio graphically, the anteroposterior talar-first metatarsal angle improved from degrees to 10 degrees, and the lateral first metatarsal angle improved from 20 degrees to 3 degrees.....	47
Fig.23: This 69-year-old woman had a 2-year history of midfoot pain and medioplantar lump, with rocker bottom deformity and sagging at the tarsometatarsal joint. The patient was treated with realignment plantar closing-wedge resection and fusion of the first and second tarsometatarsal joints, resulting in correction of the lateral talar first metatarsal angle from 25 degrees to 14 degrees.....	48
Fig.24: Preoperative clinical photos (a, b) and X-rays (c, d) of the patient's left foot before operation.....	52

Fig.25:A needle is inserted into the target lesser ray tarsometatarsal articulation under image intensifier and arthroscopy is performed with the needle as the landmark (a). This can facilitate the identification of the joint by arthroscopy. After dorsal capsulotomy, the articular cartilage is debuded with an arthroscopic osteotome under arthroscopic guide (b). After articular cartilage debridement (c), microfracture of the subchondral bone is performed with arthroscopic awl (d) (66).....56

Fig.26: Preoperative clinical photos (a, b) and X-rays (c, d) of the patient's left foot before operation (66).....57

Fig27: clinical photos(a,b) and x ray(c,d) of the patient left foot 20 months after operation (66).....57

### **Introduction**

The Lisfranc's joint or tarsometatarsal articulation of the foot, is named for Jacques Lisfranc's ,a field surgeon in Napoleon's army, Lisfranc's described an amputation performed through this joint because of gangrene that developed after an injury incurred when a soldier fell off a horse with his foot caught in the strip<sup>(1)</sup>.

Tarso metatarsal or Lisfranc's injury account for 0.2% of all fractures. Incidence of this uncommon injury is reported as approximately 1 per 55,000 persons per year. It can occur in all ages but is more common in the third decade and is more common in males. Subtle Lisfranc's sprain and diastasis have become more commonly diagnosis in athletes<sup>(2)</sup>.

Fracture dislocations/subluxations of the tarsometatarsal joint are complex injuries that are often misdiagnosed. Prompt recognition and treatment of Lisfranc's injuries decrease the likelihood of long-term squeals<sup>(3)</sup>.

Lisfranc's injury is treated conservative or operative according to stability of joint; conservative by a removable plastic cast or boot and operative by closed or open reduction and internal fixation.



### Aim of Work

The aim of this study is to explain this injury focused on anatomy, mechanism of injury, diagnosis, classification, treatment and complications.

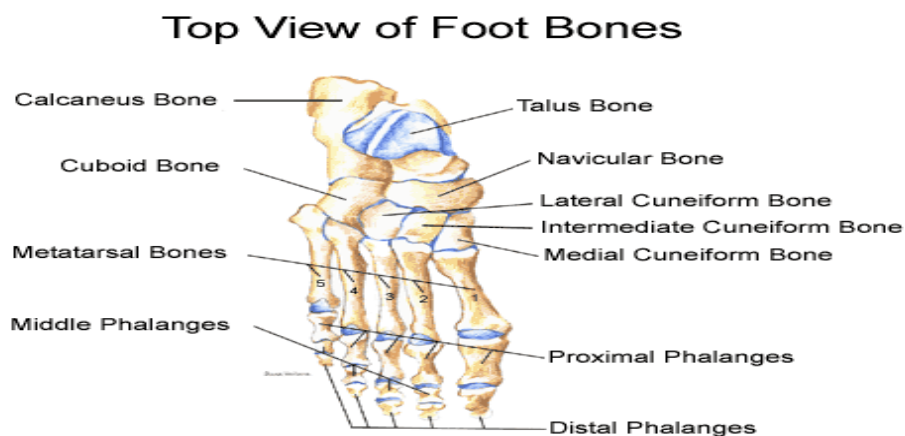
## Anatomy of The midfoot

### Skeletal system

The foot consists of three anatomic areas considered the hind foot, midfoot, and the forefoot. The midfoot, or Tarsus, consists of the three cuneiforms, cuboid, and tarsonavicular (Fig.1). The tarsometatarsal joint or Lisfranc's joint consists of the juncture between the midfoot and forefoot. The tarsometatarsal joint complex consists of the articulation of the bases of the five metatarsals <sup>(4)</sup> with the three cuneiforms and cuboid bone (Fig.2).

### Movement

The movement permitted between the tarsal and the metatarsal bones are limited to slight gliding of the bones upon each other.



Fig,1: foot bones (4).

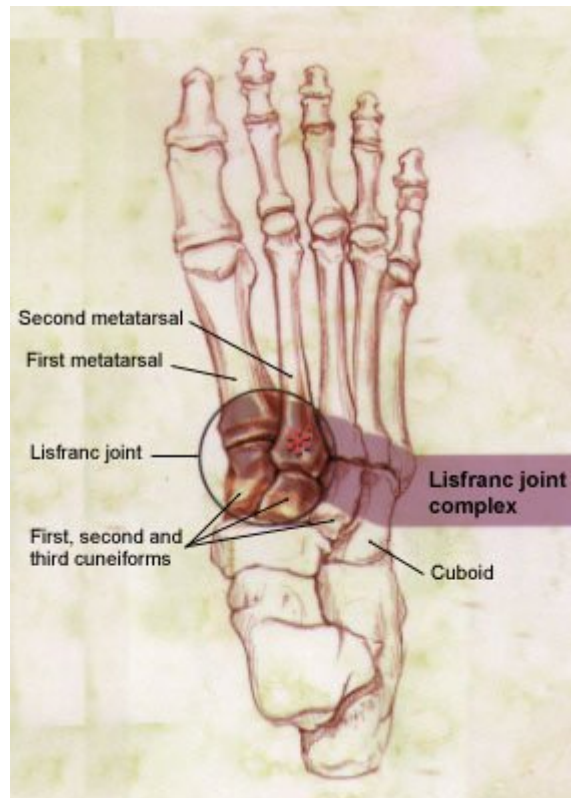


Fig.2: lisfranc's complex (3).

## **Composition of joint complex**

1<sup>st</sup> metatarsal – medial cuneiform.

2<sup>nd</sup> metatarsal – middle cuneiform.

3<sup>rd</sup> metatarsal – lateral cuneiform.

4<sup>th</sup> and 5<sup>th</sup> metatarsal – cuboid.

## Anatomy

---

The foot is generally considered to consist of a long medial longitudinal arch and a shorter transverse arch, the latter being most readily defined at the level of the tarsometatarsal joint complex.

The transverse arch present at the level of the midfoot consist of cascade of the distal articular surfaces of cuneiforms and cuboid that like a Roman arch <sup>(5)</sup>, it is stable because its dorsal surface is wider than its plantar circumference (Fig. 3).

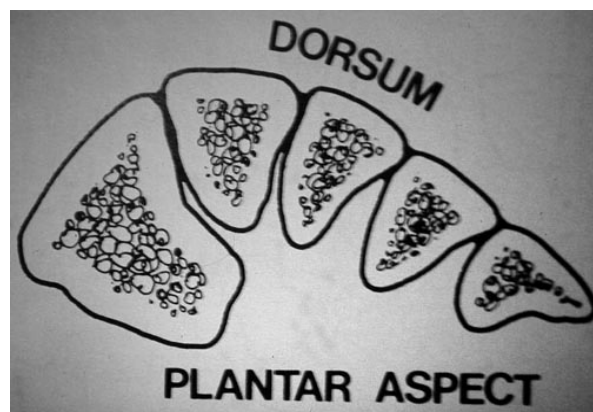


Fig.3: Roman arch (5).

## Anatomy

---

The second metatarsal base is inset proximally into the tarsal bones; the base of this metatarsal represents the "keystone" of the metatarsal arch and the cornerstone of reduction of tarsometatarsal injuries <sup>(6)</sup> .

Proximal end of the second metatarsal is tightly recessed between first and third cuneiforms; this mortise configuration effectively locks entire tarsometatarsal complex, preventing medial or lateral translation, no significant dislocation of metatarsals or

Cuneiforms can occur unless this bone is disrupted; for this reason, pure transmetatarsaltarsal dislocations rarely occur <sup>(7)</sup> .

### **Ligaments**

Lisfranc's ligament is the dorsal Interosseous (oblique and large) ligament between the plantar aspect of medial cuneiform and the second metatarsal base (Fig.4). This particular ligament is very well developed and often holds a piece of the metatarsal base attached to it when the remainder of the metatarsal is dislocated <sup>(8)</sup> . With the exception of Lisfranc's ligament, however, the plantar ligaments are much. in about 20% of patients, two separate bands of this ligament are present (dorsal and plantar); in patients with two separate filamentous bands, partial ligament injuries are possible.

## **Functions of lisfranc ligament:**

- 1- The strongest dorsal midfoot ligament.
- 2- Connect lateral metatarsals to the medial cuneiform.
- 3- Reinforces bony stability of base of the 2nd metatarsal between medial and lateral cuneiforms <sup>(9)</sup> .

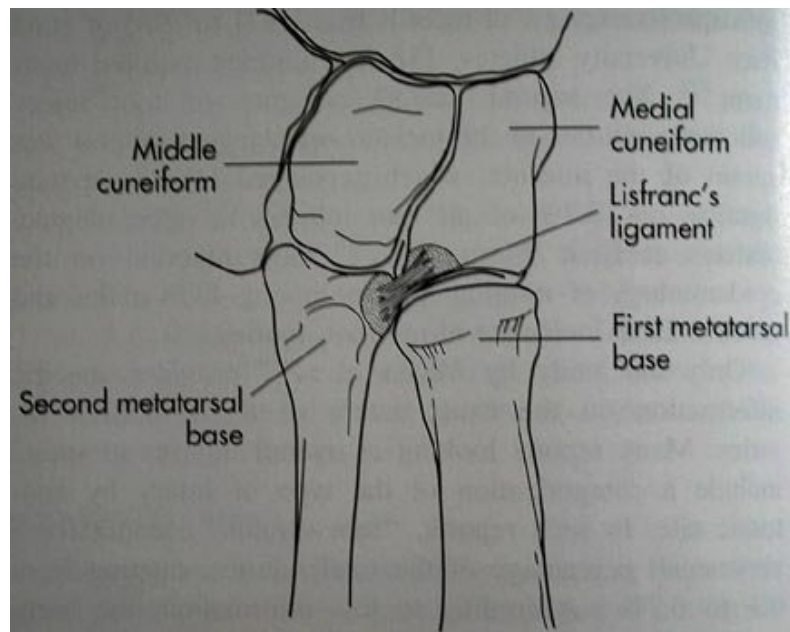


Fig.4: Lisfranc's ligament (9).

## Other ligaments

There are Interosseous ligaments: connect 2, 3, 4 and 5 metatarsal bases both dorsal and plantar (stronger and larger).

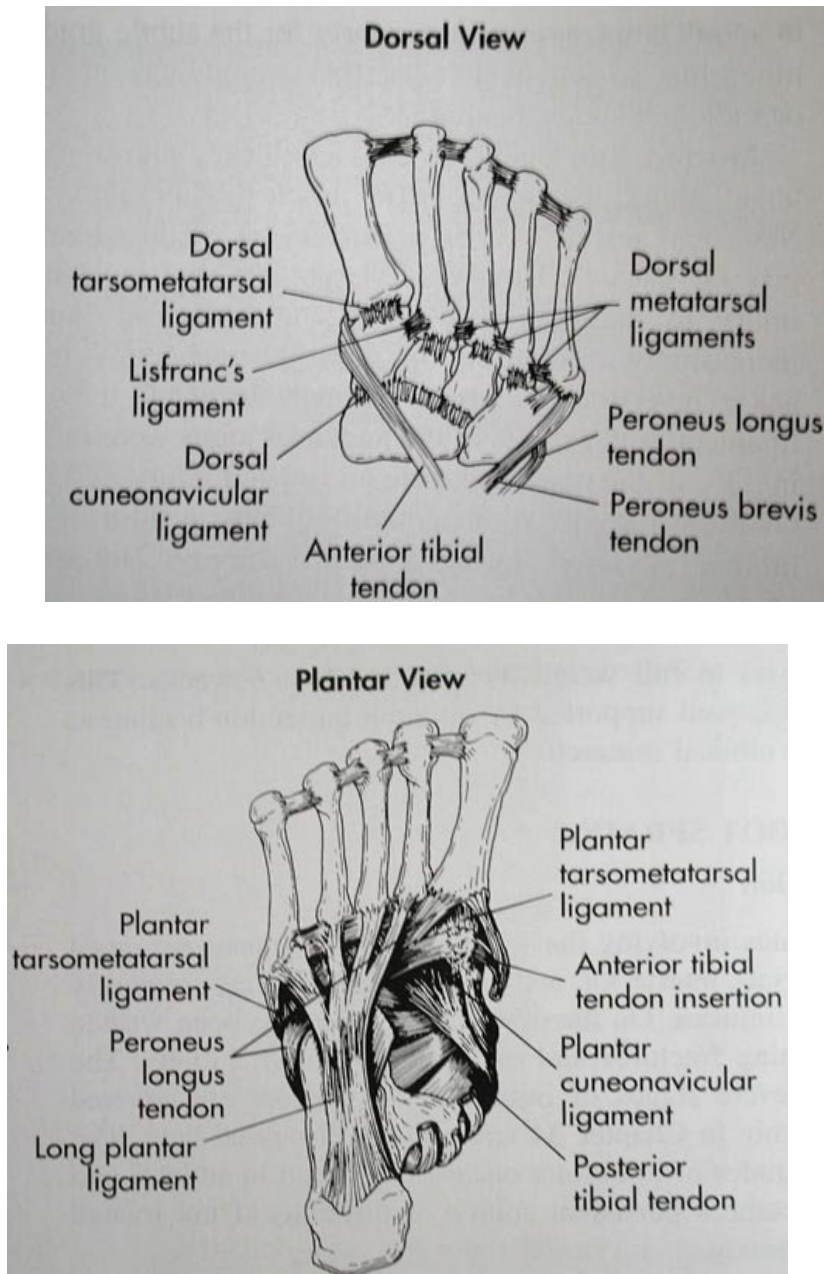


Fig.5: Interosseous ligaments (8).