

ROLE OF ULTRASOUND GUIDED RADIOFREQUENCY ABLATION OF BENIGN THYROID NODULES

Essay

Submitted for partial fulfillment of Master Degree in Radiodiagnosis

Presented by

Mohamed Reyad Abolfotoh Lasheen

M.B.B.Ch

Supervised by

Prof. Dr. Hanaa Abdel Kader Abdel Hamed

Professor of radiodiagnosis

Faculty of medicine - Ain Shams University

Dr. Merhan Ahmed Nasr

Lecturer of radiodiagnosis

Faculty of medicine - Ain Shams University

Dr. Mohamed Hussein Abd El Bary

Lecturer of radiodiagnosis

Faculty of medicine - Helwan University

Faculty of Medicine

Ain Shams University

2016

دور التردد الحراري الموجه بالموجات فوق الصوتية في حرق عقد الغدة الدرقية الحميدة

دراسة مقدمة من الطبيب

محمد رياض أبو الفتوح لاشين

بكالوريوس الطب والجراحة

توطئة للحصول على درجة الماجستير في الأشعة التشخيصية

تحت إشراف

أ.د/ هناء عبد القادر عبد الحميد

أستاذ الأشعة التشخيصية

كلية الطب - جامعة عين شمس

د/ ميرهان أحمد نصر

مدرس الأشعة التشخيصية

كلية الطب - جامعة عين شمس

د/ محمد حسين عبد الباري


مدرس الأشعة التشخيصية

كلية الطب - جامعة حلوان

كلية الطب

جامعة عين شمس

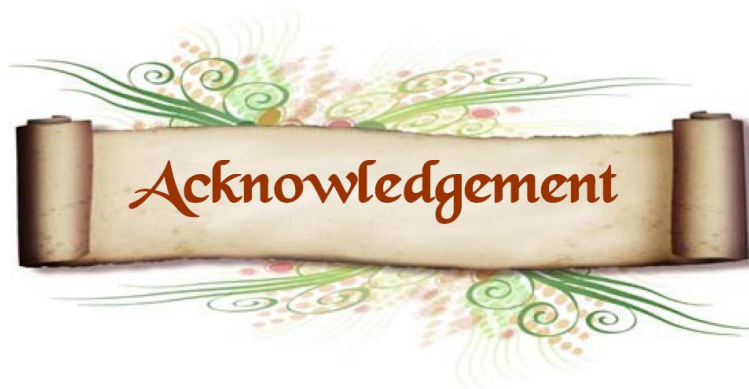٢٠١٦



وَقُلْ اَعْمَلُوا فَسَيَرَى اللّٰهُ
عَمَلَكُمْ وَرَسُولُهُ وَالْمُؤْمِنُونَ

سورة التوبة رقم الآية ١٠٥





*First and foremost, my deep gratefulness and indebtedness is to **Allah**, the Most Gracious and the Most Merciful.*

*I wish to express my deep gratitude and respect to **Prof. Dr. Hanaa Abdel Kader Abdel Hamed**, professor of radio-diagnosis, faculty of medicine, Ain Shams University, for her valuable advices, continuous encouragement, judicious guidance and kind support at this study.*

*I would like to express my great thanks to **Dr. Mohamed Hussein Abd El Bary**, lecturer of Radio-diagnosis, Faculty of Medicine, Helwan University for his kind assistance and support.*

*I would like to express my great thanks to **Dr. Merhan Ahmed Nasr**, lecturer of Radio-diagnosis, Faculty of Medicine, Ain Shams University for her kind assistance and support.*

I would also like to dedicate this work to the soul of my parents and my sister who did care, support and teach me a lot.



Mohamed Reyad

Contents

Chapter	Page
Introduction and aim of the work	1
Gross and ultrasound anatomy of thyroid gland	4
Pathology and ultrasound imaging of thyroid nodules	17
Technique and role of ultrasound guided radiofrequency ablation of thyroid nodules	39
Summary and conclusion	65
References	68
Arabic summary	١

LIST OF ABBREVIATIONS

Abbreviation	Name
AFTNs	Autonomously Functioning Thyroid Nodule
AJCC	American Joint Committee on Cancer
AP	Anteroposterior
BTA	British Thyroid Association
CBC	Complete Blood Count
cm	Centimeter
CT	Computed Tomography
d	Day
EA	Ethanol Ablation
FNAC	Fine-Needle Aspiration Cytology
g	Gram
HIFU	High-Intensity Focused Ultrasound
IS	Isthmus
kg	Kilogram
kHz	Kilohertz
LC	Longus colli muscle
min	Minute
ml	Milliliter
mm	Millimeter
PLA	Percutaneous Laser Ablation
RF	Radiofrequency

RFA	Radiofrequency Ablation
SCM	Sternocleidomastoid muscle
SM	Strap muscles
Th	Thyroid
TR	Transverse
Tra	Trachea
UICC	Union for International Cancer Control
US	Ultrasound
W	Watt

List of figures

Chapter 1 " Gross and ultrasound anatomy of thyroid gland"		
Figure 1.1	Illustrates thyroid gland anatomy	5
Figure 1.2	Illustrates muscular covering of the thyroid gland	5
Figure 1.3	Lateral view showing posterior and medial relations of thyroid gland	6
Figure 1.4	Illustrates Blood supply of thyroid gland	8
Figure 1.5	Illustrates Distribution of thyroid arteries and veins	8
Figure 1.6	Numeric classification system of cervical nodes	10
Figure 1.7	Illustrates recurrent laryngeal nerves and superior laryngeal nerves	11
Figure 1.8	Normal US appearance of thyroid in transverse view	13
Figure 1.9	Thyroid US Measurements of the width, depth, and isthmus	15
Figure 1.10	Thyroid US Measurements of the length	16
Chapter 2 " Pathology and ultrasound imaging of thyroid nodules "		
Figure 2.1	Gross picture of follicular adenoma	18
Figure 2.2	Gross picture of colloid nodule	18
Figure 2.3	Gross picture of Hashimoto's thyroiditis	19
Figure 2.4	Gross picture of multinodular goiter	20
Figure 2.5	Shape of thyroid nodules	22
Figure 2.6	Margin of thyroid nodules	23
Figure 2.7	Internal content of thyroid nodules	24
Figure 2.8	Echogenicity of thyroid nodules	25
Figure 2.9	Calcifications of thyroid nodules	26
Figure 2.10	Hypoechoic halo of thyroid nodule	27
Figure 2.11	Vascular pattern of flow in thyroid arteries	28
Figure 2.12	Graphic compilation of BTA U Classification	30
Figure 2.13	BTA U1 classification	31
Figure 2.14	BTA U2 (a) classification	32
Figure 2.15	BTA U2 (b) classification	32
Figure 2.16	BTA U2 (c) classification	32
Figure 2.17	BTA U2 (d & e) classification	33

Figure 2.18	BTA U2 (d & e) classification	33
Figure 2.19	BTA U2 (f) classification	33
Figure 2.20	BTA U3 (a) classification	34
Figure 2.21	BTA U3 (b) classification	34
Figure 2.22	BTA U3 (c) classification	35
Figure 2.23	BTA U4 (a) classification	35
Figure 2.24	BTA U4 (b) classification	35
Figure 2.25	BTA U4 (c) classification	36
Figure 2.26	BTA U4 (d) classification	36
Figure 2.27	BTA U5 (a) classification	36
Figure 2.28	BTA U5 (b) classification	37
Figure 2.29	BTA U5 (c) classification	37
Figure 2.30	BTA U5 (d) classification	38
Figure 2.31	BTA U5 (e) classification	38
Chapter 3 " Technique and role of ultrasound guided radiofrequency ablation of thyroid nodules"		
Figure 3.1	Ionic agitation and formation of frictional heat	39
Figure 3.2	Schematic and pictorial representation of focal thermal ablation	40
Figure 3.3	Diagram illustrates the interdependency of temperature and radius around a single needle electrode	40
Figure 3.4	Various radiofrequency electrode designs	44
Figure 3.5	Proper placement of grounding pads for RFA	45
Figure 3.6	Positions of operator and patient during RFA	46
Figure 3.7	Three-method approach method employing electrode	47
Figure 3.8	US image showing trans-isthmic approach	48
Figure 3.9	US images showing danger triangle	49
Figure 3.10	Transisthmic approach and the moving shot technique	50
Figure 3.11	US images of moving shot technique showing complete ablation of nodule margins	51
Figure 3.12	US images of well-ablated thyroid nodule	52
Figure 3.13	Abscess formation and ablated nodule rupture	53
Figure 3.14	Subcapsular hematoma that developed during electrode insertion	55
Figure 3.15	First-degree skin burns at the electrode puncture site	55
Figure 3.16	Chart illustrates results of volume reduction at the last follow up in previous studies	58

List of cases

Case 1	RFA of single predominantly solid thyroid nodule	60
Case 2	RFA of two solid/cystic thyroid nodules	61
Case 3	RFA of single cystic thyroid nodule	62
Case 4	RFA of single predominantly solid thyroid nodule (three sessions performed)	63
Case 5	RFA of single predominantly solid thyroid nodule (two sessions performed)	64

List of Tables

Chapter 1 " Gross and ultrasound anatomy of thyroid gland"		
Table 1.1	Numeric classification system of cervical nodes	9
Chapter 3 " Technique and role of ultrasound guided radiofrequency ablation of thyroid nodules"		
Table 3.1	Complications and side effects of RFA of thyroid nodules	54
Table 3.2	Previous studies' results of volume reduction in patients who underwent RFA for cold thyroid nodule	57
Table 3.3	Previous studies' results of patients who underwent RFA for AFTN	59