Introduction

Morbid obesity is one of the most important health issues in the world. Medical and surgical strategies aiming at weight reduction have been pursued. Surgery is the best treatment option in the management of obese patient, so it is currently the only effective therapy at achieving weight loss with significant improvement or resolution of comorbidities and increase in life expectancy ***(Piazza et al., 2011).***

In 1997, Rutledge with the purpose to carry out an ideal weight loss operation which should be effective, easy to perform and safe, introduced laparoscopic Mini-Gastric Bypass (LMGB). The procedure consists of a long lesser-curvature gastric tube with a side-to-side gastrojejunostomy performed 180–220 cm distal to the Treitz' ligament ***(Rutledge, 2001).***

The MGB was developed to overcome operative difficulties and risks of Roux-en-Y gastric bypass. It is considered an appealing alternative to Roux-en-Y gastric bypass, with an easier technique and safer outcome in the short-term and after 5 years of follow-up ***(Lee et al., 2008).***

The R-Y limb is avoided because of the long sleeve gastric tube, which eliminates the risks related to the second anastomosis and to the mesentery opening, including obstruction, and internal hernia that may all be further precipitated by pregnancy ***(Naef et al., 2010).***

Noun et al showed that MGB is an effective, relatively low-risk, and low-failure bariatric procedure. In addition, it can be easily revised, reversed, or sleeved when needed. In comparision to Roux-en-Y gastric bypass, MGB can be regarded as a simpler, safer, and easy-exit procedure ***(Noun et al., 2012).***

However, controversies about the relative safety of this procedure remain, mainly the incidence of marginal ulcer and reflux esophagitis ***(Lee et al., 2007).***

Aim of the Work

In our study, we aimed to study the efficacy, safety and feasibility of laparoscopic mini-gastric bypass in management of morbid obesity.

Anatomy and Physiology of the Stomach

The stomach is a remarkable organ with important digestive, nutritional, and endocrine functions. The stomach stores and facilitates the digestion and absorption of ingested food, and it helps regulate appetite. To provide intelligent diagnosis and treatment, the physician and surgeon must understand gastric anatomy, physiology, and pathophysiology. This includes a sound understanding of the mechanical, secretory and endocrine processes through which the stomach accomplishes its important functions. It also includes a familiarity with the common benign and malignant gastric disorders of clinical significance ***(Flora et al., 2008).***

The stomach is readily recognizable as the asymmetrical, pear-shaped, most proximal abdominal organ of the digestive tract. The part of the stomach attached to the esophagus is called the cardia. Just proximal to the cardia at the gastroesophageal (GE) junction is the anatomically indistinct but physiologically demonstrable lower esophageal sphincter. At the distal end, the pyloric sphincter connects the stomach to the proximal duodenum. The stomach is relatively fixed at these points, but the large midportion is quite mobile ***(Mercer et al., 2002).***

The superior-most part of the stomach is the distensible floppy fundus, bounded superiorly by the diaphragm and laterally by the spleen. The angle of His is where the fundus meets the left side of the GE junction. Generally, the inferior extent of the fundus is considered to be the horizontal plane of the GE junction, where the body (corpus) of the stomach begins. The body of the stomach contains most of the parietal (oxyntic) cell. The body is bounded on the right by the relatively straight lesser curvature and on the left by the more curved greater curvature. At the angularis incisura, the lesser curvature turns rather abruptly to the right, marking the anatomic beginning of the antrum, which comprises the distal 25 to 30% of the stomach ***(Ashley et al., 1999).***

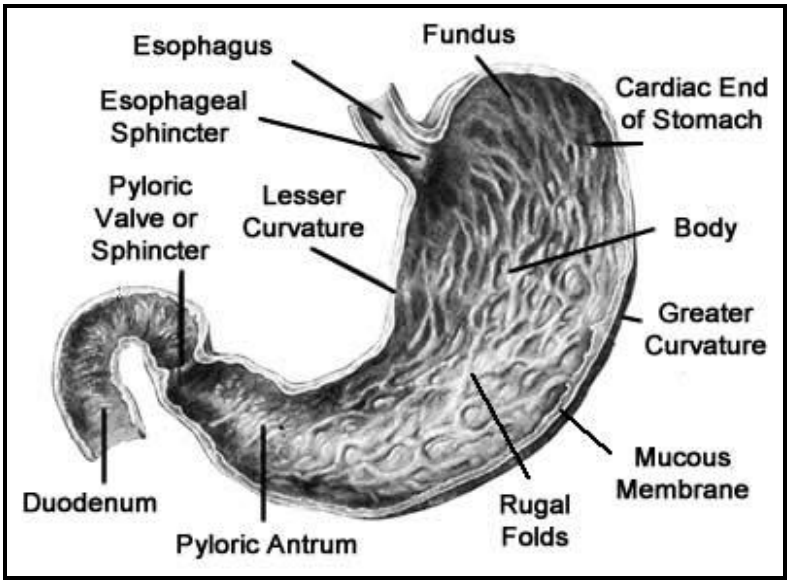

Figure (1): Parts of the stomach ***(Mercer et al., 2002).***

The organs that commonly surround the stomach are the liver, colon, spleen, pancreas, and occasionally the kidney. The left lateral segment of the liver usually covers a large part of the anterior stomach. Inferiorly, the stomach is attached to the transverse colon by the gastrocolic omentum. The lesser curvature is tethered to the liver by the hepatogastric ligament, also referred to as the lesser omentum or pars flaccida. Posterior to the stomach is the lesser omental bursa and the pancreas ***(Mercer et al., 2002).***

The stomach is the most richly vascularized portion of the alimentary tube. The large majority of the gastric blood supply is from the celiac axis via four named arteries. The left and right gastric arteries form an anastomotic arcade along the lesser curvature, and the right and left gastroepiploic arteries form an arcade along the greater gastric curvature. The consistently largest artery to the stomach is the left gastric artery, which usually arises directly from the celiac trunk and divides into an ascending and descending branch along the lesser gastric curvature ***(Orringer et al., 2007).***

The second largest artery to the stomach is the right gastroepiploic artery, which arises consistently from the gastroduodenal artery behind the first portion of the duodenum. The left gastroepiploic artery arises from the splenic artery, and, together with the right gastroepiploic artery, forms the rich gastroepiploic arcade along the greater curvature ***(Leung, 2003).***

The right gastric artery usually arises from the hepatic artery near the pylorus and hepatoduodenal ligament, and runs proximally along the distal stomach. In the fundus along the proximal greater curvature, the short gastric arteries and veins arise from the splenic circulation ***(Orringer et al., 2007).***

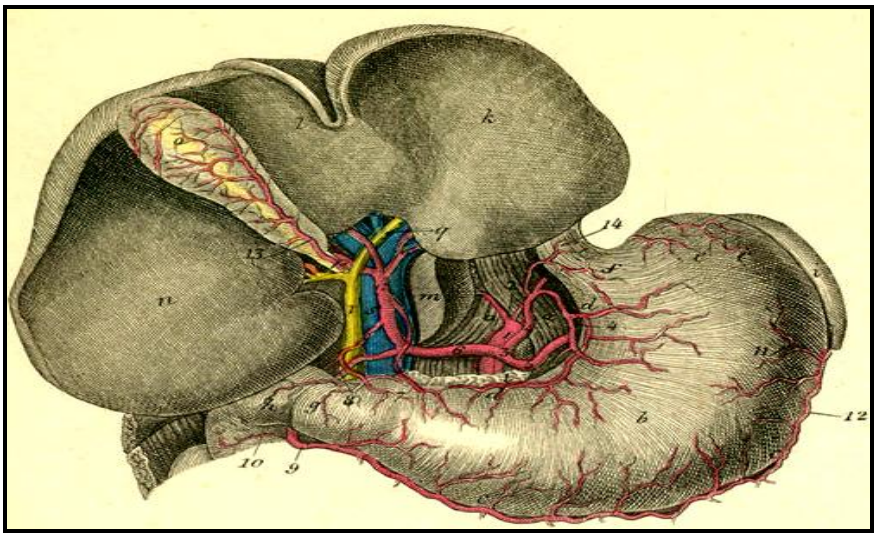

Figure (2): Stomach, liver and spleen with their arteries and the portal vein. The liver is elevated ***(Orringer et al., 2007).***

a) Medial diaphragmatic crura. b) Anterior surface of stomach. c) Stomach, greater curvature. d) Stomach, lesser curvature. e) Stomach, fundus (s. saccus coecus). f) Stomach, cardia. g) Pylorus. h) Duodenum. i) Lien (s. spleen). k) Liver left lobe. l) Liver, quadrate lobe. m) Liver, caudate lobulus (s. lobulus Spigelii). n) Liver, right lobe. o) Gallbladder (s. vesica fellea). p) Cystic duct. q) Hepatic duct. r) Bile duct (s. ductus choledochus). s) Portal vein. t) Pancreas.

1. Descending abdominal aorta.
2. Inferior phrenic artery.
3. Celiac artery (s. tripus Halleri).
4. Left gastric artery.
5. Splenic artery.
6. Hepatic artery
7. Right gastric artery.
8. Gastroduodenal artery.
9. Right gastroepiploic artery.
10. Pancreaticoduodenal artery.
11. Short gastric arteries.
12. Left gastroepiploic artery.
13. Cystic artery.
14. Inferior esophageal artery.

The veins draining the stomach generally parallel to the arteries. The left gastric (coronary vein) and right gastric veins usually drain into the portal vein, though occasionally the coronary vein drains into the splenic vein. The right gastroepiploic vein drains into the superior mesenteric vein near the inferior border of the pancreatic neck, and the left gastroepiploic vein drains into the splenic vein ***(Leung, 2003).***

Generally speaking, the gastric lymphatics parallel the blood vessels. The cardia and medial half of the corpus commonly drain to nodes along the left gastric and celiac axis. The lesser curvature side of the antrum usually drains to the right gastric and pyloric nodes, while the greater curvature half of the distal stomach drains to the nodes along the right gastroepiploic chain. The proximal greater curvature side of the stomach usually drains into nodes along the left gastroepiploic or splenic hilum. The nodes along both the greater and lesser curvature commonly drain into the celiac nodal basin ***(Orringer et al., 2007).***

Both the extrinsic and intrinsic innervation of the stomach plays an important role in gastric secretory and motor function. The vagus nerves provide the extrinsic parasympathetic innervation to the stomach. From the vagal nucleus in the floor of the fourth cerebral ventricle, the vagus traverses the neck in the carotid sheath and enters the

mediastinum, where it gives off the recurrent laryngeal nerve and divides into several branches around the esophagus. These branches come together again above the esophageal hiatus and form the left (anterior) and right (posterior) vagal trunks ***(Johnson, 2006).***

Near the GE junction the anterior vagus sends a branch (or branches) to the liver in the gastrohepatic ligament, and continues along the lesser curvature as the anterior nerve of Latarjet. Similarly, the posterior vagus sends branches to the celiac plexus and continues along the posterior lesser curvature. The nerves of Latarjet send segmental branches to the body of the stomach before they terminate near the angularis incisura as the "crow's foot," sending branches to the antropyloric region. There may be additional branches to the distal stomach and pylorus that travel near the right gastric and/or gastroepiploic arteries ***(Orringer et al., 2007).***

In 50% of patients, there are more than two vagal nerves at the esophageal hiatus. The branch that the posterior vagus sends to the posterior fundus is termed the *criminal nerve of Grassi*. This branch typically arises above the esophageal hiatus and is easily missed during truncal or highly selective vagotomy (HSV). Vagal fibers originating in the brain synapse with neurons in Auerbach's myenteric plexus and Meissner's submucosal plexus ***(Johnson, 2006).***

There are four distinct layers of the gastric wall: mucosa, submucosa, muscularis propria, and serosa. The inner layer of the stomach is the mucosa, which is lined with columnar epithelial cells of various types. Beneath the basement membrane of the epithelial cells is the lamina propria, which contains connective tissue, blood vessels, nerve fibers, and inflammatory cells ***(Mercer et al., 2002).***

Beneath the lamina propria is a thin muscle layer called the *muscularis mucosa*, the deep boundary of the mucosal layer of the gut. The epithelium, lamina propria, and muscularis mucosa constitute the mucosa ***(Ashley et al., 1999).***

The epithelium of the gastric mucosa is columnar glandular. The gastric glands are lined with different types of epithelial cells, depending upon their location in the stomach. There are also endocrine cells present in the gastric glands. Progenitor cells at the base of the glands differentiate and replenish sloughed cells on a regular basis. Throughout the stomach, the carpet consists primarily of mucus-secreting surface epithelial cells (SECs) that extend down into the gland pits for variable distances. These cells also secrete bicarbonate and play an important role in protecting the stomach from injury due to acid, pepsin, and/or ingested irritants. In fact, all epithelial cells of the stomach (except the endocrine cells) contain carbonic anhydrase and are capable of producing bicarbonate ***(Antonioli & Madara, 1998).***

In the fundus and body, the glands are more tubular and the pits are deep. Parietal and chief cells are common in these glands. Histamine-secreting enterochromaffin-like (ECL) cells and somatostatin-secreting D cells are also found. Parietal cells secrete acid and intrinsic factor into the gastric lumen, and bicarbonate into the intercellular space. Chief cells secrete pepsinogen I, which is maximally activated at a pH of 2.5. They tend to be clustered toward the base of the gastric glands. When stimulated, the chief cells produce two immunologically distinct proenzyme forms of pepsinogen: predominantly pepsinogen I and some pepsinogen II, most of which is produced by SECs (Surface epithelial cells) ***(Ashley et al., 1999).***

In the antrum, gastrin-secreting G cells and somatostatin-secreting D cells are present. A variety of hormone-secreting cells are present in various proportions throughout the gastric mucosa. Histologic analysis suggests that in the normal stomach, 13% of the epithelial cells are oxyntic (parietal) cells, 44% are chief (zymogenic) cells, 40% are mucous cells, and 3% are endocrine cells ***(Feldman, 2002).***

Deep to the muscularis mucosa is the submucosa, which is rich in branching blood vessels, lymphatics, collagen, various inflammatory cells, autonomic nerve fibers, and ganglion cells of Meissner's autonomic submucosal plexus. The collagen-rich submucosa gives strength to GI anastomoses. The mucosa and submucosa are folded into the

grossly visible gastric rugae, which tend to flatten out as the stomach becomes distended ***(Ashley et al., 1999).***

Below the submucosa is the thick muscularis propria (also referred to as the muscularis externa), which consists of an incomplete inner oblique layer, a complete middle circular layer (continuous with the esophageal circular muscle and the circular muscle of the pylorus), and a complete outer longitudinal layer (continuous with the longitudinal layer of the esophagus and duodenum). Within the muscularis propria is the rich network of autonomic ganglia and nerves that make up Auerbach's myenteric plexus. The outer layer of the stomach is the serosa, also known as the visceral peritoneum. This layer provides significant tensile strength to gastric anastamoses ***(Feldman, 2002).***

Classification and Complications of Obesity

Classification

The most widely accepted measure of obesity is the body mass index (BMI) which is calculated by dividing a patient's mass in kilograms by the square of his or her height in meters. A normal BMI is considered to range from 18.5 to 24.9 kg/m2, BMI between 25.0 and 29.9 is considered overweight, BMI of 30 or greater is classified as obese; this is further subdivided into Class I, II, or III, as shown in Table, super morbid obese if BMI above 50, super super morbid obese if ≥ 60 ***(Pouliot et al., 2004).***

Table (1): Obesity Categories and disease risk ***(Pouliot et al., 2004).***

			Men ≤ 102cm (≤ 40 in)	>102 cm (<40 in)
	BMI kg/m^2	Obesity Class	Women ≤ 88 cm (≤ 35 in)	>88 cm (>35 in)
Underweight	<18.5		—	—
Normal[b]	18.5–24.9		—	—
Overweight	25.0–29.9		Increased	High
Obesity	30.0–34.9	I	High	Very high
	35.0–39.9	II	Very high	Very high
Extreme obesity	≥40	III	Extremely high	Extremely high

It may be important to consider other factors besides the BMI, such as total muscle mass and waist circumference as extremely muscular individual may have an elevated BMI

without being overweight, Waist circumference has been shown to be an excellent indicator of abdominal fat mass, a circumference greater than 88 cm (35 inch) in women or 102 cm (40 inch) in men strongly correlates with an increased risk of obesity related disease ***(Pouliot et al., 2004).***

Causes:

Obesity results from a long term imbalance between energy intake and energy expenditure, favoring positive energy balance, expansion of adipose lipid storage, and adipogenesis. The mechanisms of this disease, greatly influenced by genetic predisposition, reside in the pathways between the gut, the adipose mass and the brain. Various hormones and neuropeptides are responsible for communication among body organs to influence consumption, absorption, and metabolism ***(Leibowitz & Wortley, 2004).***

The relative contributions of genetics and environment to the etiology of obesity have been evaluated in many studies. Although it varies from study to study, 30% to 40% of the variance in BMI can be attributed to genetics and 60% to 70% to environment. The interaction between genetics and environment is also important. In a given population, some people are genetically predisposed to develop obesity, but that genotype may be expressed only under certain adverse environmental conditions, such as high-fat diets and sedentary lifestyles ***(Leibowitz & Wortley, 2004).***

1-High-energy intake:

Dietary changes over the past 30 to 40 years have led to proliferation of energy-dense foods rich in fat and sugar, particularly carbonated beverages. Foods high in fat do not produce satiety as well as foods rich in carbohydrate. This leads to over consumption of food ***(Wilding, 2006).***

2-Physical inactivity:

Low levels of physical activity, even if caloric intake is within normal limits, may not offset intake. Use of labor-saving devices, preferences of riding in a car instead of walking, and increases in passive forms of leisure (eg: television, computers) have led to an obesity-prone population ***(Chang & Lauderdale, 2005).***

3-Endocrine disorders:

A-Growth hormone deficiency (GHD):

Patients with GHD have an abnormal body composition with increased body fat and decreased lean body mass. Patients are often overweight or obese with central adiposity ***(Wilding, 2006).***

B-Cushing syndrome:

Weight gain is a prominent symptom in Cushing's syndrome. There is an accompanying deposition of fat in face, neck, abdomen and mediastinum ***(Wilding, 2006).***