

Abdominal wall dehiscence: current status in emergency settings

Submitted for partial fulfillment for the requirements of M.Sc. in General Surgery

By

**Mahmoud Abdelmonem Ameen Biomy
M.B.B.Ch.**

Under supervision of

**Prof. Dr. Sayed Ahmed Marei MD.
Professor of general surgery
Faculty of medicine, Cairo University**

**Prof. Dr. Ayman Mohammed Attet Elsamadoni MD.
Professor of general surgery
Faculty of medicine,cairo university**

**Prof. Dr. George Abd elfady Nashed MD.
Professor of general surgery
Faculty of medicine, Cairo University**

**Faculty of medicine
Cairo University
2012**

Key word

Incisions - Wound Healing- Abdominal- Emergency Settings
Exploratory

Abstract

The proliferation phase which is the phase of granulation tissue forms in, the wound space begins in the 3 postoperative day and lasts for several weeks. The most important factor in this phase are fibroblasts which move to the wound and are responsible for the collagen synthesis [3,4]. The maturation phase begins in the 7 postoperative day and lasts for 1 year or more, continued collagen deposition and remodeling contribute to the increased tensile strength of wounds

Acknowledgment

First and foremost, I feel always indebted to **ALLAH**, the kind and merciful.

I would like to express my deepest gratitude and sincerest thanks to ***Prof. Dr. Sayed Ahmed Marei***, Professor of General Surgery, Cairo University for giving me the privilege to work under his supervision.

Many thanks to ***Prof. Dr. Ayman el samadoni***, Professor of General & vascular Surgery, Faculty of Medicine, Cairo University for his support, encouragement and valuable advices throughout this work.

Words are not enough to express my great thanks and deep appreciation to ***Prof. Dr. George abd elfady***, professor of general surgery, Cairo University for his effort, comments, ideas, constructive criticism and support throughout this thesis.

A very special thanks to my wife **Dr. Maysa Marawan** and to all my family and my colleagues for their support and encouragement throughout this work.

List of figures

<u>Figure 1: Structures of anterior abdominal wall</u>	4
<u>Figure 2: Muscles of anterior abdominal wall</u>	6
<u>Figure 3: Rectus sheath</u>	10
<u>Figure 4: Arteries of anterolateral abdominal wall</u>	13
<u>Figure 5: Lymphatics and superficial veins of anterolateral abdominal wall</u>	15
<u>Figure 6: Nerves of the Anterolateral Abdominal Wall</u>	16
<u>Figure 7: Midline incision</u>	29
<u>Figure 8: Liver laceration in patient presented with haemoperitoneum</u> ..	43
<u>Figure 9: laparotomy in patient with perforated duodenal ulcer</u>	44
<u>Figure 10: laparotomy in patients with intestinal obstruction</u>	45
<u>Figure 11: dehiscent laparotomy wound due to wound infection</u>	48
<u>Figure 12 Dehiscent surgical wound due to Poor nutrition and anemia</u> ...	51
<u>Figure 13 Abdominal wound dehiscence due to mechanical stress</u>	52
<u>Figure 14 Abdominal wound dehiscence due to excessive edema</u>	53
<u>Figure 15: A burst abdomen resutured by retention sutures</u>	55
<u>Figure 16: Stages in mass closure of the midline incision</u>	63
<u>Figure 17: Retention sutures tied and held in position supported by rubber tubing</u>	66

List of tables

<u>Table 1:</u> presentation of cases with wound dehiscence	75
<u>Table 2:</u> emergency presentation & type of incision for dehisced cases .	75
<u>Table 3:</u> Degree of dehiscence	76
<u>Table 4:</u> Risk factors contributing to wound dehiscence in our study	77
<u>Table 5</u> Risk factors per patient developed dehiscence and time of occurrence	77
<u>Table 6:</u> Management of dehisced cases	78
<u>Table 7:</u> The outcome of dehisced cases	79

Index

Introduction and aim of work.....	1
Literature review:	
• Chapter 1: Anatomy of anterior abdominal wall.....	3
• Chapter 2: Wound healing.....	17
• Chapter 3: Abdominal wall incisions and exploratory laparotomy.....	27
• Chapter 4: Wound dehiscence.....	46
• Chapter 5: Abdominal wall closure.....	57
Patients and methods.....	70
Results.....	72
Discussion.....	80
Summary and conclusion.....	86
References.....	88
Arabic summary.....	102

Introduction

&

Aim of work

Introduction and aim of work

Surgical wound dehiscence after laparotomy remains a serious complication. It presents a mechanical failure of wound healing of surgical incisions. Surgical incisions stimulate the healing process which in reality is a complex and continuous process with four different stages: Hemostasis, inflammation, proliferation, and maturation (**Chin et al, 2005**).

During hemostasis, platelets aggregate, degranulate and activate blood clotting. The clot is degrading, the capillaries dilate and fluids flow to the wound site, activating the complement cascade.

Macrophages, lysis of cells and neutrophils are a source of cytokines and growth factors that are essential for normal wound healing (**Chin et al, 2005**).

The proliferation phase which is the phase of granulation tissue forms in, the wound space begins in the 3 postoperative days and lasts for several weeks. The most important factor in this phase is fibroblasts which move to the wound and are responsible for the collagen Synthesis (**Waqer et al, 2005, West et al, 2005**).

The maturation phase begins in the 7th postoperative day and lasts for 1 year or more, continued collagen deposition and remodeling contribute to the increased tensile strength of wounds (**Chin et al, 2005**).

Conditions associated with increased risk of wound dehiscence are anemia, hypoalbuminemia, malnutrition, malignancy, jaundice, obesity and diabetes, male gender, elderly patients and specific surgical

procedures as colon surgery or emergency laparotomy which are associated with wound disruption (Sorensen et al ,2005).

Aim of work

The aim of this study is evaluation of the current status of abdominal wound dehiscence in emergency settings at kasr alaini emergency department concerning the incidence, evaluation of risk factors of wound dehiscence and which of them can be prevented, and the outcome of this condition (morbidity & mortality).

Chapter 1

*Anatomy of the anterior
abdominal wall*

Chapter (1)

Anatomy of the anterior Abdominal wall

The outline of the anterior abdominal wall is approximately hexagonal. It is bounded superiorly by the arched costal margin (with the xiphisternal junction at the summit of the arch). The lateral boundary on either side is, arbitrarily, the mid-axillary line (between the lateral part of the costal margin and the summit of the iliac crest). Inferiorly, on each side, the anterior abdominal wall is bounded in continuity, by the anterior half of the iliac crest, inguinal ligament, pubic crest and pubic symphysis (**Vishy Mahadevan, 2009**).

Layers of the anterior abdominal wall

The anterior abdominal wall is a multi-layered structure (Figure 1). From the surface inwards, the successive layers are:

- Skin
- Superficial fascia (comprising two layers)
- A musculo-aponeurotic layer (which is architecturally complex and composed of several layers).
- A properitoneal adipose layer
- Parietal peritoneum (**Grievous, 2006**).
- Transversalis fascia

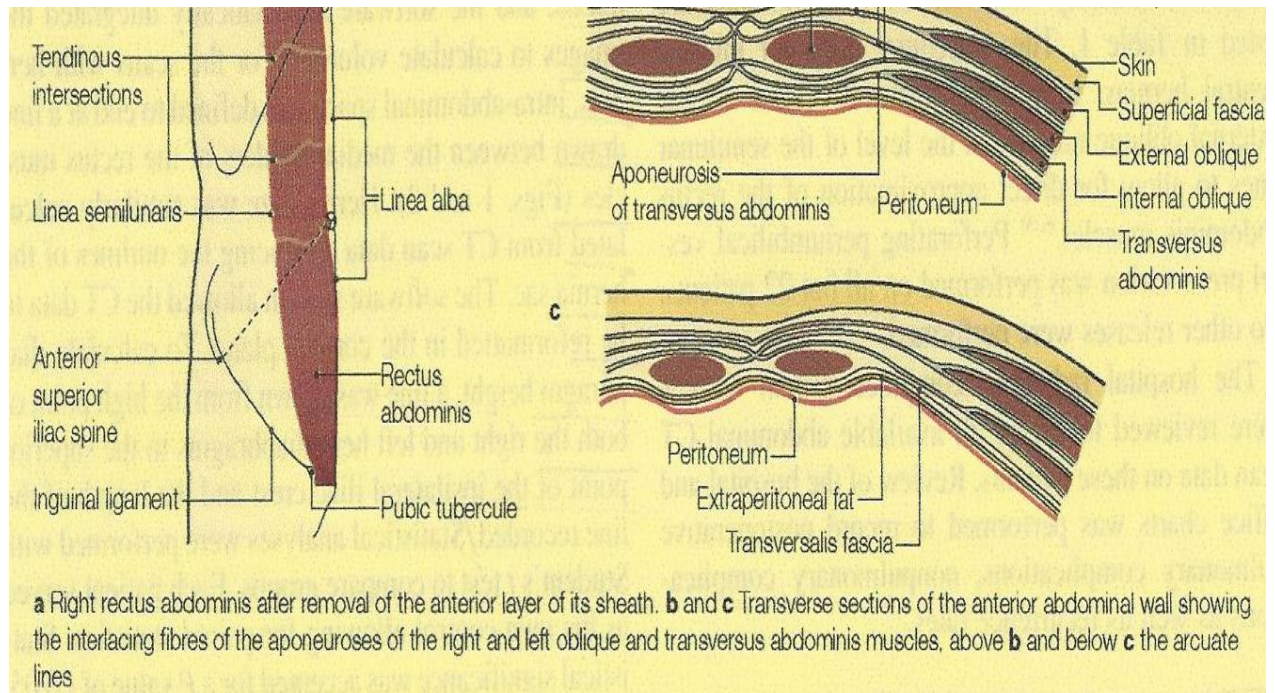


Figure 1: structures of anterior abdominal wall
(Moore et al, 2006).

Skin:

The skin covering the anterior abdominal wall is thin compared to that of the back, and is relatively mobile over the underlying layers except at the umbilical region, where it is fixed.

Natural elastic traction lines of the skin (also known as skin tension lines or Kraissl's lines) of the anterior abdominal wall are disposed transversely. Above the level of the umbilicus these tension lines run almost horizontally, while below this level they run with a slight inferomedial obliquity. Incisions made along, or parallel to, these lines tend to heal without much scarring, whereas incisions that cut across these lines tend to result in wide or heaped-up scars (Gray et al, 1985).

Beneath the skin, there is the subcutaneous areolar tissue and superficial fascia. Over the lower thorax and epigastrium, the superficial

fascia consists of one layer. This layer is thin and less organized than in the lower abdomen. In the lower abdomen it becomes more definitively bilaminar. Just superior to the inguinal ligament it can be divided into a superficial fatty stratum, termed Camper's fascia, and a deeper, stronger, and more elastic membranous layer called Scarpa's fascia (Gray et al, 1985).

The superficial layer is thick, areolar, and contains a variable amount of fat. This layer continues into the perineum, and in females, it continues over the labia majora. The deep layer is more membranous and contains elastic fibers. It is separated from the underlying deep fascia by a loose areolar layer. Inferiorly, it fuses with the deep fascia of the thigh, medial portion of the inguinal ligament, and pubic tubercle along the line of the fold of each groin (Peter et al, 1989).

Musculo-aponeurotic layer:

The abdominal wall contains multiple large, musculofascial units which serve several functional purposes (Figure 2). Laterally, from external to internal, there are two paired external oblique, internal oblique, and transversus abdominis muscles. There are two paired midline muscle groups which include the rectus abdominis muscle and the pyramidalis. All of these muscles contribute to increasing intraabdominal pressure and aid in micturition, defecation, and parturition (Grevious et al, 2006).

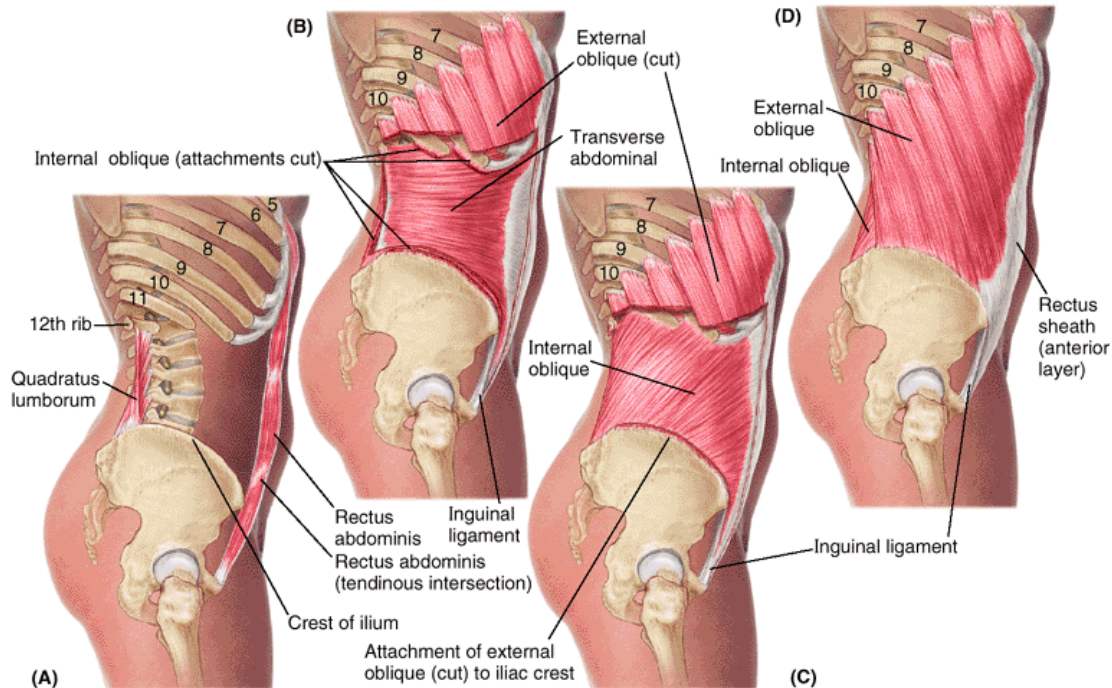


Figure 2: muscles of anterior abdominal wall (A) Rectus abdominis (B) Transversus abdominis (C) Internal oblique (D) External oblique (**Moore et al, 2006**)

Rectus Abdominis

Rectus abdominis muscle lies on either side of the vertical midline. Each muscle arises by two tendons; a lateral tendon from the pubic crest, and a medial tendon from the upper and anterior surfaces of the pubic symphysis. The two tendons unite a short distance above the pubis to give rise to a single muscle belly which runs upwards to attach to the anterior surfaces of the 7th, 6th and 5th costal cartilages. The upper part of the muscle usually shows three transverse tendinous intersections; one at the level of the umbilicus, one at the level of the xiphoid tip and one halfway between the two. On either side of the rectus abdominis, the musculo-aponeurotic plane is made up of three overlapping arrangement of flat muscular sheets, The outermost of these is the external oblique muscle, the innermost is the transversus abdominis muscle and the intermediate layer is the internal

oblique muscle. of these, only the external oblique has an attachment above the level of the costal margin. Followed anteromedially, each of these muscles becomes aponeurotic. These aponeuroses, between them, enclose the rectus abdominis muscle; the envelope is termed the rectus sheath (Gray et al, 1985; Peter et al, 1989 ; Skandalakis et al, 1999).

The external oblique muscle

Arises by fleshy digitations from the outer aspect of each of the lower eight ribs near their costochondral junctions. From this origin the muscle fibres fan downwards and forwards. The fibres that arise from the lower two ribs run downwards to insert onto the anterior half of the outer lip of the iliac crest; the posterior edge of this mass of fibres constitutes the free posterior border of the muscle. The remainder of the muscle ends in a broad aponeurosis. The lower edge of this aponeurosis extends between the anterior superior iliac spine and the pubic tubercle. It is rolled inwards to form a narrow and shallow gutter, and constitutes the inguinal ligament. The rest of the external oblique aponeurosis runs in front of the rectus abdominis muscle of its side and interdigitates with the contralateral aponeurosis along the vertical midline. Below the level of the xiphoid process this interdigitation helps to form a raphe, the linea alba (Gray et al, 1985; Peter et al, 1989 ; Skandalakis et al, 1999) .

The internal oblique muscle

Lies immediately deep to the external oblique. It arises, in continuity, from the lateral two-thirds of the guttered inguinal ligament, from a central strip along the anterior two-thirds of the iliac crest, and from the lateral margin of the lumbar fascia along the lateral border of the quadratus