Study of the Anatomy of the Superficial Musculo-Aponeurotic System & Its Application in Face Lift Surgery

Thesis

Submitted for Partial Fulfillment

Of M.D. Degree in General Surgery

By

Tamer Hassan El-Sherif

(M.B., B.Ch.) (M.Sc. in general surgery)
Faculty of Medicine, Cairo University

Supervised By

Prof. Dr. Ahmed Sherif Gamal Karim

Professor of General & Plastic Surgery
Faculty of Medicine-Cairo University

Prof. Dr. Almoetassem Bellah Mohamed El Sherif

Professor of Anatomy
Faculty of Medicine-Cairo University

Prof. Dr. Fathi Rezk Khodair

Professor of General & Plastic Surgery
Faculty of Medicine-Cairo University

Faculty of medicine-Cairo University

Cairo 2007

Abstract

Key Words : SMAS – Anatomy

Superficial musculoaponeurotic System (SMAS) Is an Important Facial layer . The relation of the SMAS to Facial Nerve branches , mimetic muscles and retaining ligaments Must be well know to the surgeon before doing face lift Surgery . Histological Studies revealed the Presence of Muscle fibres within the retaining ligaments in still birth, Which prevent skin sagging during childhood .

Acknowledgement

First and foremost, I would like to thank God for his grace and mercy, and for giving me the effort to complete this work.

I would like to express my deepest gratitude and greatest respect to professor Dr. Ahmed Sherif Gamal Karim, Professor of general surgery, faculty of medicine, Cairo University, for his continuous support, everlasting encouragement, assistance and experienced advice that made this work see the light

My sincere gratitude is addressed to Prof. Dr. EL Moatasem Bellah Mohamed Elsherif, Professor of Anatomy, faculty of medicine, Cairo University. For his precious advice, step by step guidance, his kind supervision and encouragement that made this work possible.

My deep thanks to Prof. Dr. Fathi Rezk Khodair, professor of general and plastic surgery, faculty of medicine, Cairo university, For his constant support , cooperation, valuable supervision and his sincere help during this work.

I wish to thank deeply all my professors, my seniors and my colleagues for helping me, directly or indirectly to carry on this research.

Last , but not least , my deepest gratitude goes to my parents and my wife, their constant love, support and sacrifice made this work possible.

Contents

Introduction

Rational and background:

Precision in aesthetic surgery depends not only on the technical skills of the operator, but almost equally on the surgeon’s detailed knowledge of anatomy. This is particularly pertinent in dealing with aesthetic surgery of the face. A thorough knowledge of the anatomic layers and structures of the face and neck is a prerequisite for successful and safe aesthetic surgery ***(Nahai, 2005)***

The superficial musculo-aponeurotic (SMAS) has been steeped in controversy. The goal of our anatomic study is to further clarify the existence of the SMAS & its application in face life surgery ***(Thaller et al., 1989).***

In ***1976 Mitz & Peyronie***, the first clinically relevant anatomic description of the superficial facial layers of the cheek area. Subsequent investigations further elucidated the so called SMAS as a discrete fascial layer that divides the subcutaneous fat into two distinct layers. Superficial to the SMAS, the fat lobules are observed to be divided by multiple fibrous septa extending from the SMAS layer to the overlying dermis. Deep to the SMAS, is another layer of yellow fat lying between the fascial layer and investing fascia of the parotid gland, the masseter muscle and anteriorly, the muscles of facial expression. Superiorly the SMAS is connected to the frontalis fascia, and inferiorly, to the platysma muscle.

Jost & Levet, described the so called SMAS as merely an anatomic dissection of the superficial fascia. They proposed that the appropriate plane of dissection is beneath the parotid fascia. ***(Jost & Levet, 1984).***

The term superficial musculo-aponeurotic system (SMAS) has achieved almost universal recognition both within the plastic surgical literature and in clinical practice. Approximately 50 percent of practicing plastic surgeons include a variety of SMAS dissection as a component of their rhytidectomy. SMAS platysma face lift has been variously described by a number of authors. ***(Reas. & Aston, 1977).***

Mendelson makes rational the use of SMAS in face lift surgery, shows how that layer interacts with those above and below and convincingly demonstrates the reasons it is important to fully release the SMAS for the best effect ***(Mendelson, 1997).***

The superficial musculo-aponeurotic system (SMAS) is seen to become the investing fascia of the zygomaticus major and minor muscles in the medial cheek. The pull on the cheek flap during rhytidectomy is diffused by the attachment of the SMAS to these muscles. It is believed that this attachment accounts for the minimal change in the nasolabial crease after a skoog type Sub-SMAS facelift.

A cross-section of the mid cheek from the parotid through the commissure shows a thick prominent SMAS laterally over the parotid and masseter. This SMAS gradually attenuates medially to become the delicate investing fascia of the risorius***. (Fritz, 1992***).

The Zygomatic (McGregor's Patch) anchor the skin of the cheek to the inferior border of the zygomaticus major just posterior to the origin of the zygomaticus minor muscle. The mandibular ligaments tether the overlying skin to the ant. mandible. Both these ligaments are obstacles to the surgical maneuvers intended to advance the overlying skin. They also retrain the facial skin against gravitational changes, and they delineate the anterior border of the “Jowl” area. The platysma-auricular ligament is a thin fascial sheet that extends from the postero-superior border of the platysma and that is intimately attached to the peri-auricular skin; it serves as a surgical guide to the postero-superior border of the platysma***.(Furnas, 1989)***

The anterior platysma-cutaneous ligaments are variable fascial condensations that anchor SMAS and platysma to the dermis. They can cause anatomic disorientation with dissection of false planes into the dermis ***(Furnas, 1989).***

Aim of the work:

The aim of the work is to study anatomy of the superficial musculo-aponeurotic system (SMAS) and its application in facelift surgery and its relation to the surrounding structures of the face.

EMBRYOLOGY OF THE FACE

●*General:*

In the 4th to the 8th weeks of fetal development the normalcy of the embryo's face is determined by the timing and completeness of cell growth and migration. ***(Kissel et al., 1981).***

During the 4 th week of embryonic development, the human face begins forming with closure of the anterior neuropore. This is the time that the ectodermal cells, known as the neural crest cells and located adjacent to the neural plate, will migrate peripherally. These neural crests are fully responsible for facial, muscular and skeletal elements, in contrast to their lesser role in other areas ***(Johnson and Sulik, 1984).***

The branchial arches are the basic structures from which the face and pharynx develop. They can be recognized in an embryo at the 10-somite stage. They form in pairs flanking the stomodeum and pharynx. The first and largest arch is known as the mandibular arch. This arch has a small superior portion that contributes to the maxilla and a larger inferior portion that will contribute to the mandible, malleus, and incus. The second and only other named arch is the hyoid arch. Its contribution is to the body of the hyoid, the stapes, and adjacent neck structures. The remaining arches are smaller, and the 5th and 6th arches are rudimentary. The hyoid arch will actually grow caudally over the 3rd and 4th arches, creating a temporary cervical sinus. ***(Slavkin , 1979).***

These arches have a common structure. ***(Fig.1),*** each arch is composed of internal and external walls of endoderm and ectoderm, respectively. The center of each arch is filled with mesoderm. At the time of migration, neural crest cells go from a compact collection to dispersed isolated cells when they arrive in the branchial arches. They travel between ectoderm and mesoderm initially and then proceed throughout the mesoderm, with the exception of the central mesodermal core, which they go around***. (Moore, 1977).***

The other component of the mesoderm of each arch include an artery, a nerve, a cartilaginous bar, somatic mesoderm for muscle formation, and a cranial nerve. The cartilaginous bars in the branchial arches differentiate into the initial cartilages of the head and neck. The dorsal portion of the 1st bar will ossify and become the malleus and incus. The ventral portion of 1st bar is known as Meckel's cartilage and will form the mandible by intramembranous ossification. The dorsal portion of the second bar will become known as Reichart cartilage and will ossify to form the stapes and styloid process. The branchial arches are each supplied by a cranial nerve. The nerve to the 1st arch is the trigeminal, whose branches supply the teeth, the mucous membranes of the oral and nasal cavities, and the tongue. The 2nd arch is supplied by the facial nerve, which supplies the muscles of facial expression ***(Statalof and Selber, 2003).***

.The musculature of the face and neck are derived from the somatic cells of the branchial arches "mesodermal core". The 1st arch will contribute the muscles of mastication, which include the temporalis, masseter, and medial and lateral pterygoids, along with mylohyoid, anterior belly of the digastric, and the tensors veli palatini and tympani.

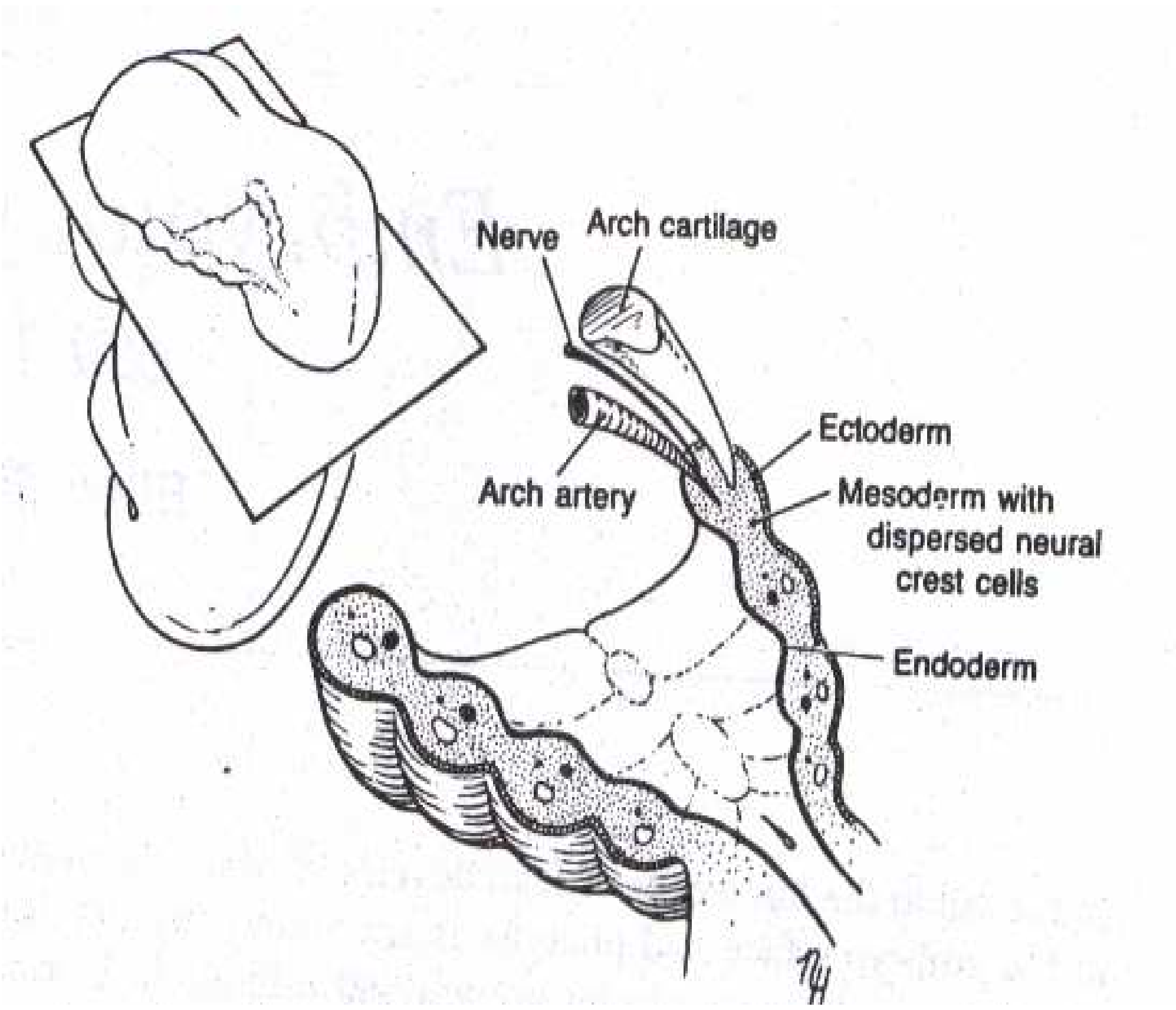

FIG. (1) Branchial arch structure in cross section.

(Moore, 1977)

The 2nd arch supplies the muscle cells for the facial expression muscles (orbicularis oris and oculi, frontalis, platysma, auricularis, and buccinator), the posterior belly of the digastric, stapedius, and stylohyoid. ***(Stal and spira, 1991).***

Formation of the face begins in the 3rd week of development with the genesis of the branchial arches and growth of the frontonasal prominence ***(Fig.2).***A streaming of neural crest cells into the mesoderm of the early facial and frontonasal prominences and laterally into the 1st and 2nd branchial arches, which will become the maxilla and mandible. These neural crest cells are believed to be responsible for the fusion of the facial prominences**.** ***(Schaeffer, 1942)***

The frontonasal prominence will contribute the philtrum and primary palate ***(Fig. 3).*** When it fuses with the maxillary prominences in the 6th to 7th weeks of development, the maxillary prominences are responsible for the lateral upper lip and maxilla and the secondary palate. The palate forms from two lateral palatine shelves that initially lie in a vertical plane adjacent to the tongue. The mandibular processes will give rise to the lower part of the cheeks, lower lip, mandible and the chin. ***(Kissel et al., 1981).***

A fusion process occurs between the different processes. The frontonasal process fuses with the maxillary process on each side along the side of the nose, around the ala and lateral side of the border of the philtrum.The maxillary process fuses with the mandibular process on each side till the oral commissure. The two mandibular processes fuse in the middle line of the lower lip and chin ***(Johson and Sulik, 1984).***

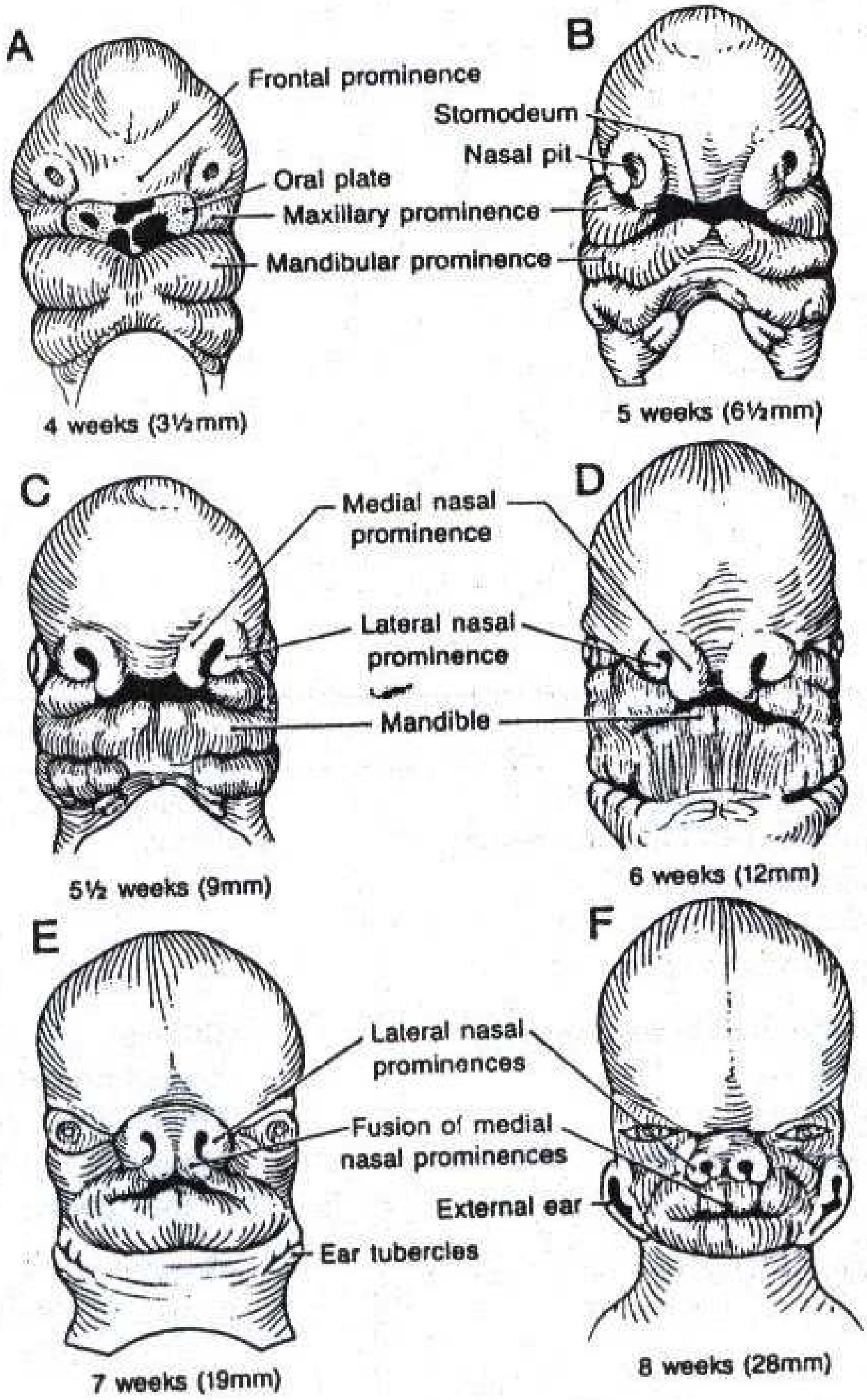

FIG.(2). Formation of facial features.

(Schaeffer,1942)

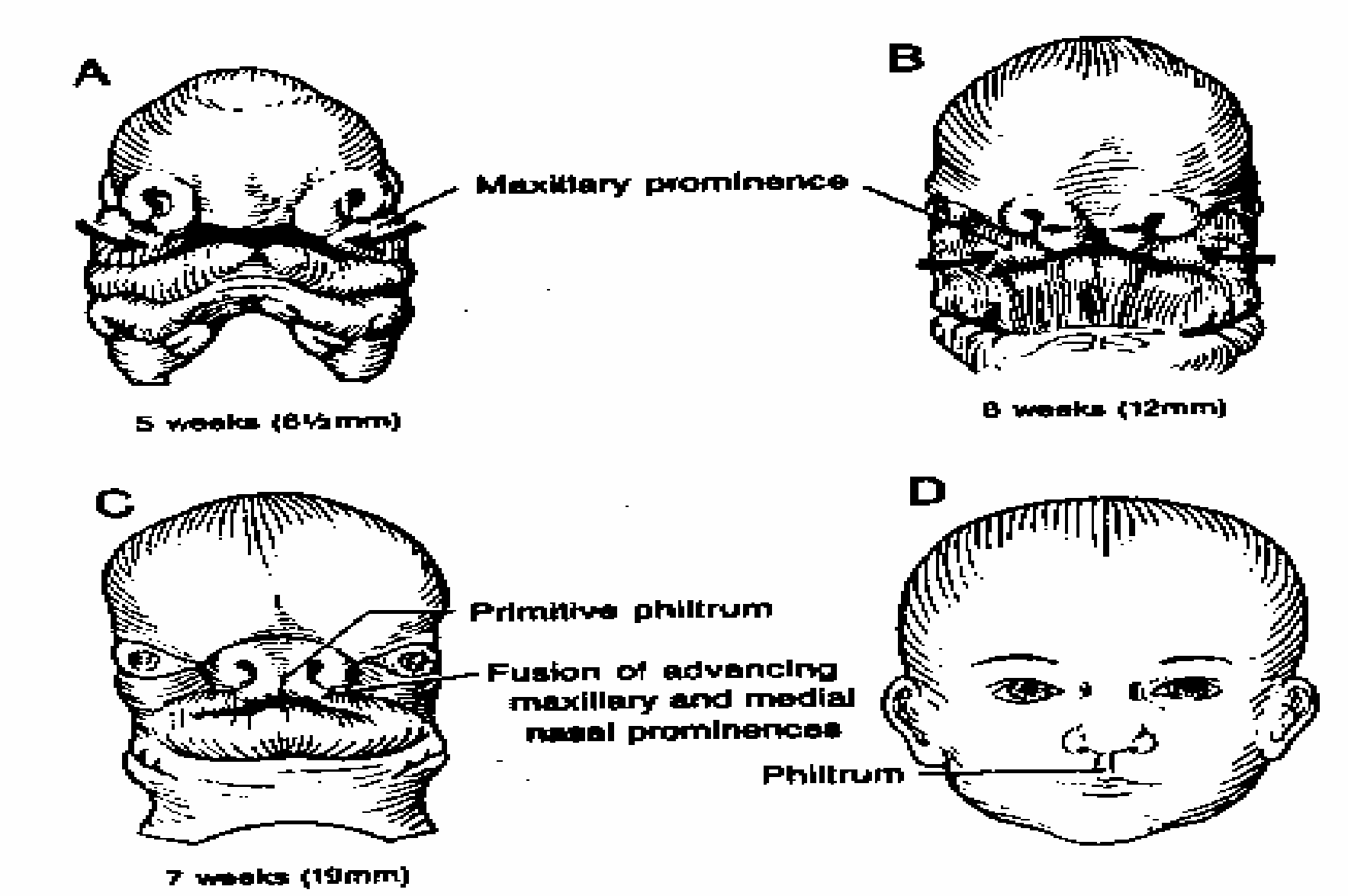

FIG. (3)Fusion of the facial prominences

(Schaeffer,1942)

●*Facial Muscles:*

The muscles of the face are derived from the first two branchial arches. The muscles of mastication arise from the mandibular arch; the mandibular division of the trigeminal nerve is in association with the early development and migration of these muscles. The muscles of facial expression are phylogenetically branchiomeric and arise from the hyoid arch. In the human embryo, at the age of six weeks, the differentiation into superficial and deep layers takes place. The superficial layer spreads over the anterior neck, the face, and the side of the head. As the face and head change shape, expand and develop specific regions, this superficial layer migrates to form the frontalis and occipitalis muscles of the head, the auricular muscles of the ear and the platysma muscle in the anterior neck and lower face. Small filaments of facial nerve which were in association with the original primordial superior layer of muscle are pulled along with these muscular migrations as early as the sixth and seventh week of embryonic life ***(Stataloff and Selber, 2003).***

The primordial deep muscle layer of the hyoid arch migrates to the region which is developing into the face proper, and begins to separate into a balanced set of muscles in order to accommodate the special sense organs of the eyes, nose, and mouth. This muscle mass will also pull along with it some small filaments of the facial nerve. The main primary, secondary, and tertiary divisions of the facial nerve will accompany the various muscle groups which are destined to register facial emotional expressions. On the whole, these muscle groups occupy the middle and lower third of the face which is devoid of any elements from the superficial primordial muscle layer ***(Johnson and Sulik, 1984***).

These muscle groups are in contact with the bony frame work of the face and in some regions with the dermis of the skin. By virtue of their close approximation and interwoven nature plus a basic common origin, all explain well the inherent, enormous capacity for reactivation of movements when a small facial nerve filament has been cut. On the other hand, when the nerve supply to the more distant, single muscles of the superficial primordial muscular layer has been cut, there is little change for reactivation because the supply often comes from a solitary nerve filament. ***(Youssef et al., 1965).***

●*Facial Nerve:*

In the two weeks old embryo, the form of the central nervous system is heralded by a thickening of the epidermis in the cephalad region into the neural plate, which then forms into the neural groove and then into the neural tube by the third embryonic week ***(Davis et al., 1956).***

At three and half weeks, a small bud like structure is found adjacent to the differentiating brain at this level. This bud forms the geniculate ganglion from which the sensory afferent fibers of the facial nerve arise. After five weeks, this evagination of the primordial geniculate ganglion has developed a small nerve trunk that has moved toward the hyoid arch ***(Gasser, 1969).***

At seven weeks, this nerve trunk moves along with the mesoderm of the hyoid arch which will differentiate into the muscles of facial expression (***Sammaro et al., 1966)***.

The facial nerve is composed of two roots; the nucleus of the motor root arises in the pons and the nucleus of the sensory root arises in the geniculate ganglion. The facial nerve is primarily a motor nerve containing