

Update On Oncoplastic Breast Surgery

Essay

Submitted for Partial Fulfillment of Master Degree
in General Surgery

By

Mohammad Ahmad Yousef Abd El-Rahim
M.B.B.CH.

Under Supervision of

Prof. Dr. Fateen Abd El-Monaem Anoos
Prof. of General Surgery
Faculty of Medicine – Ain Shams University

Dr. Karim Sabry Abd El-Samee
Lecturer of General Surgery
Faculty of Medicine – Ain Shams University

Faculty of Medicine
Ain Shams University

2014



Acknowledgment

First of all, I would like to express my deep gratitude to **ALLAH** for his care and generosity throughout my life.

would like to express my sincere appreciation to
I Prof. Dr. Fateen Abd El-Monaem Anoos,
Professor of General Surgery, Ain Shams University, for his keen supervision and guidance and his overwhelming support that has been of great help throughout this work.

I am very thankful to **Dr. Kareem Sabry abd El-Samee,** *Lecturer of General Surgery, Ain Shams University for his great support & effort throughout the whole work.*

To my beloved family for all support they have given to me.

I dedicate this work to my beloved father who have done a lot to me without waiting for anything in return and, I hope I can pay even small part of this debt to hem.

Mohammad Ahmad Yousef

INTRODUCTION

Breast Surgery is now a recognized subspecialty of General Surgery with structured training for designated Breast Surgeons. Over the recent years, Breast cancer care has been enhanced by the emergence of Specialist Breast Surgeon with training in Oncoplastic Surgical skills – Oncoplastic Breast Surgeon [1].

The term oncoplastic surgery refers to surgery on the basis of oncological principles during which the techniques of plastic surgery are used, mostly for reconstructive and cosmetic reasons. The advantage of oncoplastic surgery for breast cancer is the possibility of performing a wider excision of the tumour with a good cosmetic result [2].

Randomized controlled trials (RCTs) over the past two decades have now established that radical mastectomy and breast conserving surgery are equivalent in terms of survival provided local recurrence rates after breast conservation surgery are kept at about 1 % per annum [3, 4].

A careful evaluation of mammographic, ultrasound and sometimes MRI extent of the disease, its nearness to the nipple and the distribution of the cancer in either radial or circumferential manner are all essential to the planning and the eventual success of the oncoplastic procedures [5].

The criteria for breast conserving surgery are relative. Contrary to the traditional teaching, breast conserving surgery is feasible every time it is judged possible to achieve complete surgical excision with good cosmesis. The size of the tumour relative to the breast volume is the deciding factor in determining the suitability of breast conserving surgery [6].

It may even be suitable for women with large breasts in whom the tumour is up to 5 cm or even multifocal tumours confined to the same quadrant and when large operable tumours have been down-staged by neoadjuvant chemotherapy. Oncoplastic techniques may be used during any kind of breast conserving surgery for breast cancer [6].

1) The breast reduction techniques there are several indications and contraindications. Also, cosmetic results after breast conserving surgery of breast cancer is determined by the location of the tumor as tumors located in the medial, central or lower quadrant yields worse results compared with other locations [7,8].

2) Volume displacement procedures include local tissue rearrangement, reduction mamoplasty and mastopexy. While, volume replacement procedures include local and remote flaps from various regions of the body and implant insertion [7,8].

In general women with smaller breasts, with minimal ptosis were found to be better candidates for volume replacement procedures, e.g. local flap and latissimus dorsi flap, while women with larger and more ptotic breast would be better candidates for volume displacement procedures, e.g. adjacent tissue rearrangement, reduction mamoplasty and mastopexy [8].

AIM OF THE WORK

The aim of this work is cure of the patient coupled with partial reconstruction of the defect to achieve a cosmetically acceptable result with a satisfactory physical and psychological outcome.

Oncoplastic breast surgery has the advantage of combining the oncological and aesthetic procedure in one operation.

ANATOMY OF THE BREAST

Gross anatomy:

- **Extent and location:**

The adult female breast lies between the second and sixth ribs and between the sternal edge and the midaxillary line **Fig (1)**. Breast tissue frequently extends into the axilla as the axillary tail of Spence. Posteriorly, the upper portion of the breast rests on the fascia of the pectoralis major muscle; inferolaterally, it is bounded by the fascia of the serratus anterior [9].

- **Size and form:**

The size of the adult female breast varies widely among individuals, and considerable discrepancy in breast size is seen between the breasts of an individual woman. The breast is composed of skin, subcutaneous tissue, and breast tissue. The breast tissue includes both epithelial parenchymal elements and stroma. The epithelial component comprises about 10% to 15% of the breast mass, with the remainder being stroma. Each breast consists of 15 to 20 lobes of glandular tissue that are supported by a framework of fibrous connective tissue. The space between lobes is filled by adipose tissue. Variations in breast size are accounted for by differences in the amount of adipose tissue in the breast rather than the epithelial elements. Much of the epithelial

tissue of the breast is found in the upper outer quadrant, which is why this is the most frequent site of both benign and malignant breast disease. The lobes of the breast are subdivided into lobules, which are made up of branched tubuloalveolar glands. Each lobe ends in a lactiferous duct, 2 to 4 mm in diameter. Beneath the areola, the lactiferous ducts dilate into lactiferous sinuses and then open through a constricted orifice onto the nipple [9].

- **Nipple and areola:**

The nipple is located over the fourth intercostal space in the non pendulous breast and is surrounded by a circular, pigmented areola. Beneath the nipple and areola are bundles of radially arranged smooth-muscle fibers that are responsible for the erection of the nipple in response to a variety of stimuli. The nipple and areola contain sebaceous glands and apocrine sweat glands, but no hair follicles. In addition, the tubercles of Morgagni are nodular elevations formed by the openings of the Montgomery glands at the periphery of the areola. These glands are capable of secreting milk and are believed to represent an intermediate stage between sweat and mammary glands. The nipple and areolar region, as well as the remainder of the breast, is richly supplied with sensory innervation [9].

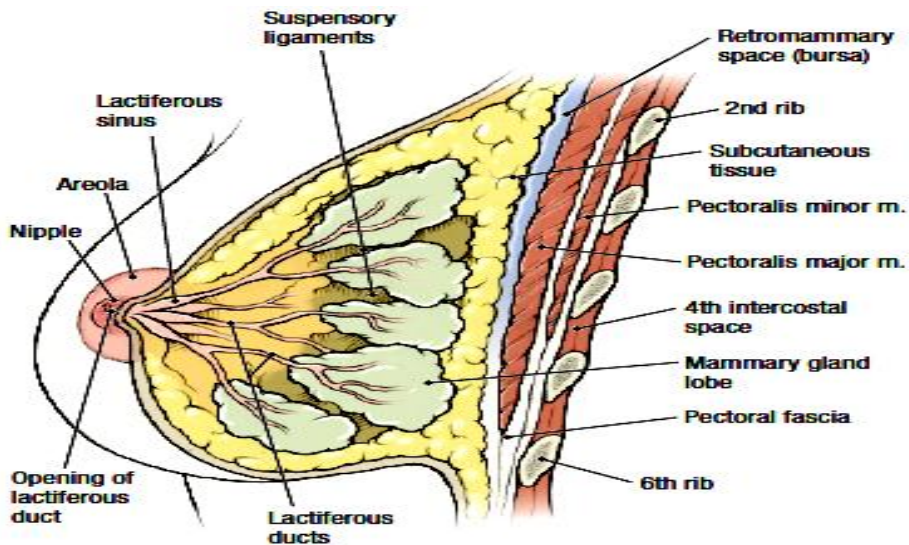


Figure (1): *Breast in sagittal section* [10].

Fascia of the breast:

The fascial framework of the breast is important in relation to clinical manifestations of disease and surgical technique. Because the breast develops as a skin appendage, it does so within the superficial fascia, such that the superficial part of the superficial fascia forms an anterior boundary and the deep layer of the superficial fascia forms a posterior boundary. In between, condensation of this interlobar fascia gives rise to ligaments of Cooper, called suspensory ligaments because they provide a supporting framework to the breast lobes **Fig (2)**. They are best developed in the upper part of the breast and are connected to both pectoral fascia and skin by fibrous extensions. In spite of these fibrous extensions, the superficial layer of superficial

fascia gives a plane of dissection between the skin and breast. The small subcutaneous fat lobules are readily differentiated from the much larger mammary fat lobules. Likewise, the retromammary space provides a ready plane of dissection between the deep layer of superficial fascia and the deep fascia of pectoralis major and serratus anterior. This structural fascial support is so intimately connected to interlobular and intralobular fascia with their enclosed ductal units, no ready plane of dissection exists within the breast substance and all surgery must be carried out by sharp dissection [11].

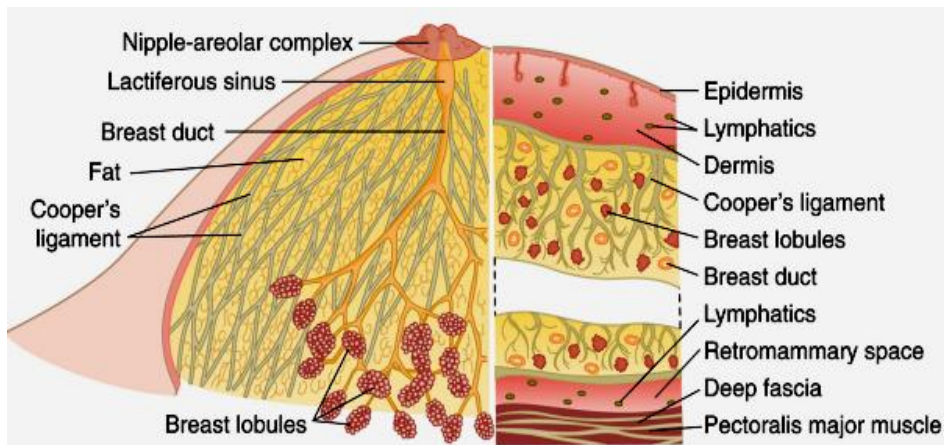


Figure (2): Cut-away diagram of a mature resting breast [12].

Vascular anatomy of the breast:

Arterial Anatomy:

There are three main sources of arterial blood supply:

- Internal mammary artery.
- Lateral thoracic artery.

- Intercostal arteries.

Many parts of mammary gland are supplied by two and sometimes three of main sources. The medial portion of gland derives its major supply from the penetrating or intercostals branches of the internal mammary artery. The entire gland derives its major supply from intercostal arteries whereas the branches of lateral thoracic artery supply the lateral portion of the gland. See **Fig (3)**.

Venous Anatomy:

The veins form a rich subareolar plexus and drain to the intercostal and axillary veins and to the internal thoracic veins [13].

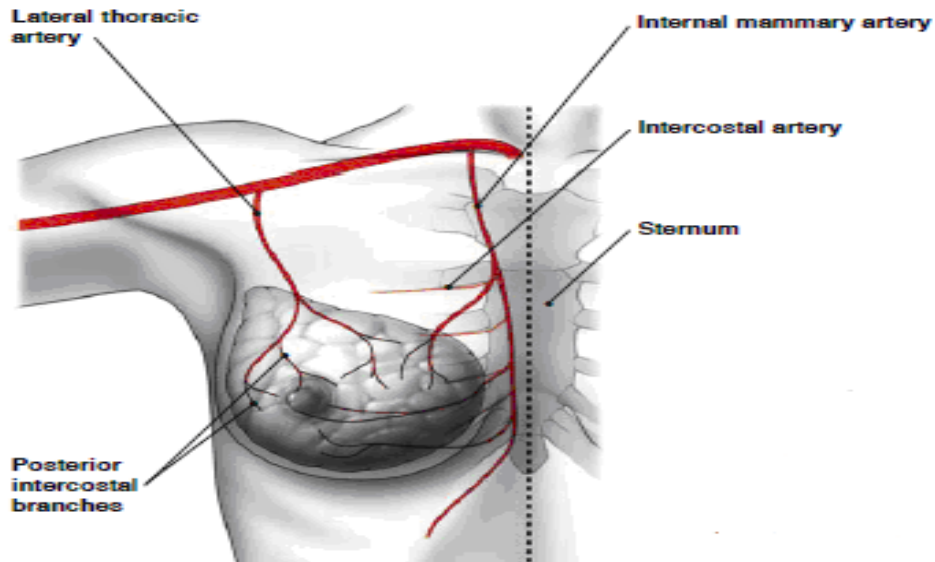


Figure (3): Arterial supply of the breast [14].

Lymphatic drainage:

The lymphatics of the breast are thin-walled, valveless vessels that drain uni directionally except when obstructed by inflammatory or neoplastic disease. The superficial subareolar lymphatic plexus drains primarily the skin of the breast, the nipple and areola, in addition to some of the central portion of the gland. This plexus is interconnected with the deep lymphatic plexus, which drains most of the breast parenchyma. Injections of radioactively labeled colloid demonstrated that about 97% of the lymphatic flow from the breast drains directly into the axillary lymph nodes, with the remaining 3% draining into the internal mammary nodes. All quadrants of the breast drain into the internal mammary nodes [9].

Anatomists described four groups of axillary lymph nodes, whereas surgeons described six groups. presents the following grouping of the 24–38 nodes [15].

The axillary lymph nodes arranged in the following groups **Fig (4)**. lateral group; along the axillary vein(four to six lymph nodes), anterior group; along the lateral thoracic vessels(four to five nodes), posterior group; along the subscapular vessels(six or seven nodes), central group; embedded in fat in the center of axilla(three or four nodes), interpectoral group; a few nodes lying between the pectoralis major and minor muscles(one to four nodes), and apical

group; which lie above the level of the pectoralis minor tendon(six to twelve nodes) efferents of all the other groups. Apical nodes are also in continuity with the supraclavicular nodes and drain into the subclavian lymph trunk, which enters the great veins directly or via the thoracic duct or jugular trunk [15].

Surgeons have traditionally divided the axillary nodes into three levels **Fig (5)**; level I nodes, inferior and lateral to the pectoralis minor; level II nodes, behind the pectoralis minor and inferior to the axillary vein; and level III nodes, medial to the pectoralis minor and against the chest wall. The interpectoral (or Rotter's) nodes are located between the pectoralis major and minor muscles along the lateral pectoral nerve. The supraclavicular nodes are contiguous with the apex of the axilla. The internal mammary nodes are located in the first six intercostal spaces within 3 cm of the edge of the sternum [15].

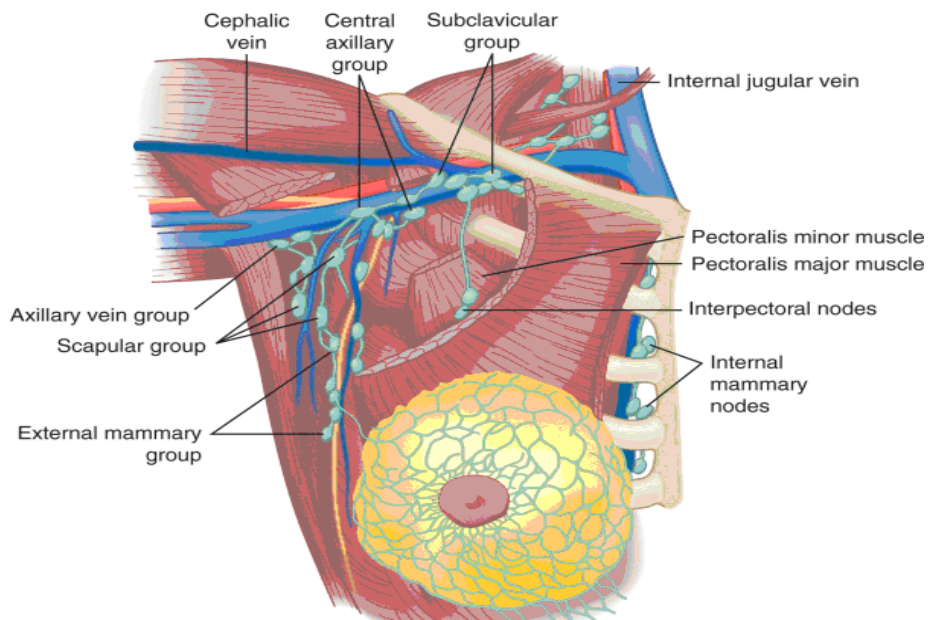


Figure (4): Lymphatic drainage of the breast [12].

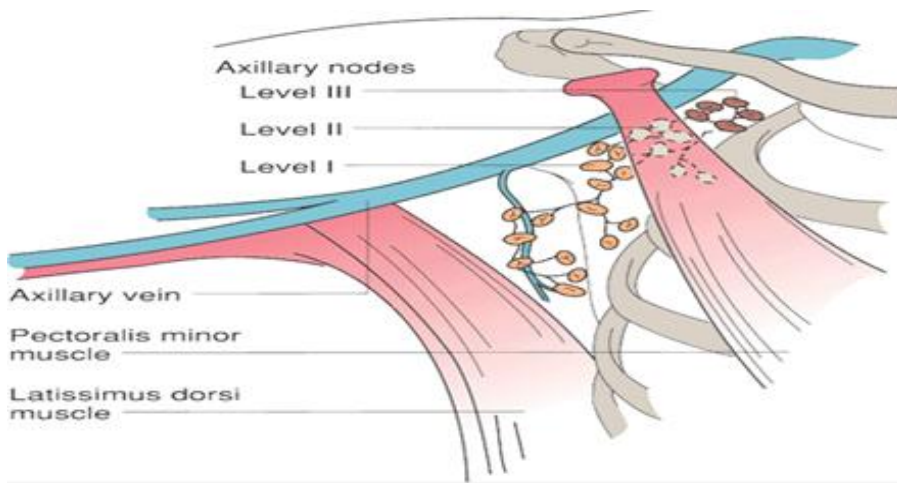


Figure (5): Division of the axillary lymph nodes [9].

BREAST AESTHETIC UNITS

In aesthetic breast surgery, surgeons choose to perform the incisions on the skin folds and anatomical sulci (axillary fold, inframammary fold, and areolar margin), thus reducing the stigma of a surgical intervention. In reconstructive surgery, this principle might not be followed owing to the oncologic priority of treatment. The localization and extent of the neoplasm determine the position of the scars. Nevertheless, the current approach still considers the aesthetic side without interfering in the local–regional treatment of disease [17].

On these grounds, in recent years, the concept of breast oncoplastic surgery emerged, which might be defined as the balance between the maximal local–regional control of breast cancer and the minimal possible trauma. In the literature on breast cancer, the breasts were described as geometric circles divided into quadrants (“mammary mass”), without taking into account the natural and anatomical shape (of a drop) or the aesthetic demarcation lines. Surgical incisions on uncovered areas of the skin are aesthetically unpleasant. One of the main stigmas associated with the full process of breast reconstruction is the scar resulting from the catheter inserted to infuse chemotherapy agents, which remains visible on the upper chest area in the vast majority of patients [16].