

Recent Trends in Management of Diabetic Foot

Essay

*Submitted in partial fulfillment of Master degree in
General Surgery*

By

Sameh Fikry Goubran Eskander

(MB.B.Ch)

Supervised By

Prof. Dr. Moemen Shafik Abou Sheloea

Professor of General Surgery
Faculty of Medicine - Ain Shams University

Dr. Hesham Mohamed Ali Omran

Lecturer of General Surgery
Faculty of Medicine - Ain Shams University

Dr. Khaled Mohamed Ali El-Gazzar

Lecturer of Plastic Surgery
Faculty of Medicine - Ain Shams University

Faculty of Medicine
Ain Shams University

2013

الطرق الحديثة في علاج القدم السكري

رسالة مقدمة من

الطبيب / سامح فكرى جبران إسكندر

(بكالوريوس الطب والجراحة)

جامعه عين شمس

توطئة للحصول على درجة الماجستير في الجراحة العامة

تحت إشراف

أ.د/ مؤمن شفيق أبو شلوع

أستاذ الجراحة العامة

كلية الطب - جامعة عين شمس

د/ هشام محمد على عمران

مدرس الجراحة العامة

كلية الطب - جامعة عين شمس

د/ خالد محمد على الجزار

مدرس جراحة التجميل

كلية الطب - جامعة عين شمس

كلية الطب

جامعة عين شمس

2013

List of Contents

Title	Page
♦ List of Contents	I
♦ List of Abbreviations	II
♦ List of Tables	IV
♦ List of Figures	V
♦ Introduction and Aim of the Work	1
♦ Review of literature	5
▪ Chapter I: Pathogenesis of Diabetic Foot	5
▪ Chapter II: Assessment of Diabetic foot	49
▪ Chapter III: Management of Diabetic foot Complications	90
▪ Chapter IV: Reconstruction of Diabetic Foot	105
▪ Chapter V: Advanced Wound Care Therapies for Non-Healing Diabetic ulcers	138
♦ Summary and Conclusion	150
♦ References	154
♦ Arabic Summary	--

List of Abbreviations

Abbreviation	
ACE	Angiotensinogen converting enzyme
PAD	Peripheral arterial disease
IDF	The International diabetes federation
WHO	World Health Organization
ICDF	International Consensus on the Diabetic Foot
SP	Substance P
GCRP	Calcitonine gene-related peptide
NPY	Neuropeptide Y
MTPJ	Metatarsophalangeal joints
DB	Diabetes Mellitus
Tc	Cytotoxic T cells
TEA	Lower extremity amputation
DCCT	Diabetes Control and Complications Trial
UKPDS	United Kingdom Prospective Diabetes Study
HBA1c	Glycohemoglobin
CBC	Complete blood count
ESR	Erythrocyte sedimentation rate
Tc-99	HMPAOTc-99 hexamethyl propylene amine oxime
CT	Computed tomography

List of Abbreviations (Cont.)

Abbreviation

PET	Positive emission tomography
Tc-99 MDP	Technetium-99 methylene diphosphonate
MRI	Magnetic resonance imaging
SPP	Laser Doppler velocimetry and measurement of skin perfusion pressure
CTA	CT angiography
PTB	Positive probe to bone
UTSA	The University of Texas San Antonio
MRSA	Methicillin-resistant Staphylococcus aureus
CRP	C reactive protein
STSGs	Split-thickness skin grafts
ALT	Anterolateral thigh
NPWT	Negative Pressure Wound Therapy
GM-CSF	Granulocyte/macrophage colony- stimulating factor
HBO	Hyperbaric oxygen
PaO2	Arterial oxygen pressure
MSCs	Mesenchymal stem cells

List of Tables

Table No	Title	Page
Table (1):	Risk factors for the development of ulcers.	30
Table (2):	Medical History	50
Table (3):	Lower extremity diabetic foot exam.....	52
Table (4):	Interpretation of the results of Ankle-Brachial Index measurement.....	63
Table (5):	Wagner classification system of diabetic foot ulcers.....	76
Table (6):	University of Texas classification system of diabetic foot ulcers.....	77
Table (7):	Pedis ulcer classification	77
Table (8):	Types of Wound dressings	100
Table (9):	Offloading devices-alternatives to TCCs	102
Table (10):	Approach to Treating a Patient With Diabetic Foot Osteomyelitis	104
Table (11):	Muscles of 1 st layer of the foot	116
Table (12):	Muscles of 2 nd layer of the foot	117
Table (13):	Muscles of 3 rd layer of the foot.....	117
Table (14):	Muscles of 4 th layer of the foot.....	118
Table (15):	Advanced wound dressings	140

List of Figures

Figure No	Title	Page
Figure (1):	The risk factors for ulceration may be distinguished by general or systemic considerations versus those localized to the foot and its pathology.....	13
Figure (2):	Role of different mechanisms in diabetic wounds and neuropathy	16
Figure (3):	Injury and inflammation in normal subjects and diabetic patients.....	18
Figure (4):	The different deformities of “at risk” diabetic foot.....	22
Figure (5):	Two different feet with “cavus foot”.....	29
Figure (6):	The factors that comprise sufficient cause for ulceration	33
Figure (7):	Diabetic patient with neuropathy, callus and claw toes using inappropriate shoes that cause repetitive trauma, thus forming the fracture of the callus and infecting the skin.....	34
Figure (8):	The risk factors for amputation are multifactorial and similar to those for ulceration.....	47
Figure (9):	Risk factors for foot ulcer and amputation in diabetic patients	48
Figure (10):	Pathogenesis of diabetic foot disorders	53
Figure (11):	Management of diabetic foot	61
Figure (12):	Diagnostic imaging plays an important role in the evaluation of diabetic foot infections	65

List of Figures (Cont.)

Figure No	Title	Page
Figure (13):	Pressure perception tested with Semmes–Weinstein monofilaments	68
Figure (14):	Determination of vibration perception thresholds using a biothesiometer or a neurothesiometer.....	70
Figure (15):	Assessment of a diabetic foot ulcer includes not only a description of the skin lesion but also the findings necessary for accurate assessment of the contributing factors and etiology.....	76
Figure (16):	Diabetic foot infections are generally considered polymicrobial, because multiple organisms are frequently found in a wound milieu. Staphylococcus and Streptococcus remain the most important organisms causing infection.....	80
Figure (17):	Diabetic foot infection.....	82
Figure (18):	Charcot foot	84
Figure (19):	Diabetic neuroarthropathy may be classified according to the anatomic location of joint involvement.	88
Figure (20):	Complications of diabetic foot	89
Figure (21):	The diabetic foot services.....	91
Figure (22):	Removable cast walker	105
Figure (23):	Scotchcast boot.....	105
Figure (24):	Reconstructive ladder in wound closure	107

List of Figures (Cont.)

Figure No	Title	Page
Figure (25):	Elliptical design to close heel defect by primary approximation.....	108
Figure (26):	A split-thickness skin graft secured to the recipient site with skin staples; a hemostatic agent is applied to the donor site.	107
Figure (27):	Medial plantar flap	110
Figure (28):	(a) The lateral heel defect after a wide resection of a recurrent malignant melanoma and a lateral calcaneal flap was designed. (b) The lateral calcaneal flap was elevated. (c) Six months after reconstruction	111
Figure (29):	A patient with a pathologic report of malignant melanoma on the heel	112
Figure (30):	Preoperative photograph showing the traumatic defect over the medial aspect of the foot with exposed bone.....	114
Figure (31):	Great toe fibular artery flap	115
Figure (32):	(a) Flexor digitorumbrevis muscle turn over flap obtained via midplantar incision (b) external offloading device applied (c) long term follow up	121
Figure (33):	(a) Muscle transplanted to foot defect (b) Early postoperative (c) Previously bulky flap	123
Figure (34):	Pre- and postoperative views of a heel defect with exposed Achilles tendon treated by free rectus abdominis muscle flap	125

List of Figures (Cont.)

Figure No	Title	Page
Figure (35):	(A–D) A “V to Y” flap was used to close an ulcer formed by the collapse of a Charcot midfoot	133
Figure (36):	An effective amputation prevention program includes regular podiatric foot care, protective shoes, and pressure reduction as well as prophylactic foot surgery combined with both patient and physician education programs	137



Acknowledgement

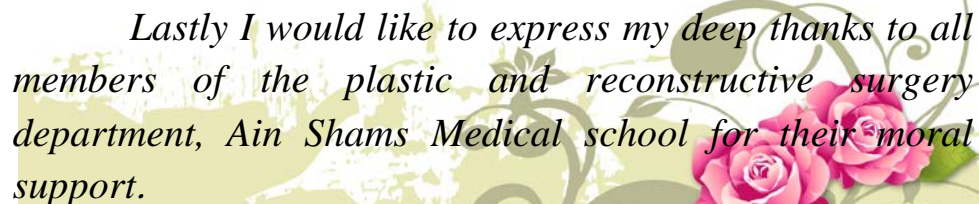
*First great thanks to “**ALLAH**” who gave me the power to complete this work. Without his care, nothing could be achieved.*

*I would like to express my sincere and deep gratitude to **Professor Moemen Abou Sheloea, Professor of General Surgery Faculty of Medicine, Ain Shams University** for sacrificing his precious time to supervise and read this work.*

*Also to would like to express my deep gratitude to **Dr. Hesham Mohamed Ali Omran, Lecturer of General Surgery Faculty of Medicine, Ain Shams University** for his support and valuable instructions. He kindly gave me much of his experience and kind efforts to make this work possible.*

*Also I would like to present my warmest thanks to **Dr. Khaled Mohamed Ali El-Gazzar Lecturer of Plastic Surgery Faculty of Medicine, Ain Shams University**. He devoted much of his time and offered me much of his valuable experience and support to accomplish this work.*

Lastly I would like to express my deep thanks to all members of the plastic and reconstructive surgery department, Ain Shams Medical school for their moral support.





Introduction and Aim of the Work





Review of Literature





Chapter I

Pathogenesis of Diabetic Foot





Chapter II

Assessment of Diabetic Foot

