

سامية محمد مصطفى



شبكة المعلومات الجامعية

بسم الله الرحمن الرحيم



سامية محمد مصطفى



شبكة المعلومات الجامعية



شبكة المعلومات الجامعية التوثيق الالكتروني والميكرو فيلم



سامية محمد مصطفى



شبكة المعلومات الجامعية

جامعة عين شمس

التوثيق الإلكتروني والميكروفيلم

قسم

نقسم بالله العظيم أن المادة التي تم توثيقها وتسجيلها
علي هذه الأقراص المدمجة قد أعدت دون أية تغيرات



يجب أن

تحفظ هذه الأقراص المدمجة بعيدا عن الغبار



سامية محمد مصطفى



شبكة المعلومات الجامعية



بعض الوثائق الأصلية تالفة



سامية محمد مصطفى



شبكة المعلومات الجامعية



بالرسالة صفحات لم ترد بالأصل



OPPLER TISSUE IMAGING (DTI) AS A NEW TECHNIQUE FOR EVALUATION OF LEFT VENTRICULAR DIASTOLIC FUNCTION

THESIS

SUBMITTED TO FACULTY OF MEDICINE, TANTA UNIVERSITY
IN PARTIAL FULFILLMENT OF THE REQUIREMENTS OF
Ms DEGREE IN CARDIOLOGY

BY

ENAS EL-SAYD DRAZ

MBBCh, (Tanta).

SUPERVISORS

Prof.Dr. Fathia Ahmed El-Shishtawy

Ass. Professor of Cardiology
FACULTY OF MEDICINE
TANTA UNIVERSITY

Prof.Dr. Ahmed Zaghlol Darwish

Ass. Professor of Cardiology
FACULTY OF MEDICINE
TANTA UNIVERSITY

Prof.Dr. Seham Fahmy Badr

Ass. Professor of Cardiology
FACULTY OF MEDICINE
TANTA UNIVERSITY




**FACULTY OF MEDICINE
TANTA UNIVERSITY
1999**

B
1C-21


بِسْمِ اللَّهِ الرَّحْمَنِ الرَّحِيمِ


"قالوا سبحانك لا علم لنا إلا ما علمتنا إنك أنت
العليم الحكيم"

صدق الله العظيم
البقرة (٣٢)



To my Husband
To my son
And to my dear
father and
mother





Acknowledgment

بسم الله الرحمن الرحيم

رب أوزعني أن أشكر نعمتك التي أنعمت عليّ وعلى والديّ
وان أعمل صالحاً ترضاه وأدخلني برحمتك في عبادك الصالحين

I always fell deeply indebted to my God . The real guide and the real supporter.

I would like to express my deepest gratitude and great appreciation to *prof. Dr. Fathia Ahmed El-Sheshtawy*, Assistant Prof. Of Cardiology, Faculty of Medicine, Tanta University , for her Cooperation, kind help and support. I shall always remember her encouragement and guidance to me.

I shall always feel indebted to *Prof. Dr. Ahmed Zaghlol Darwish* , Faculty of medicine, Tanta University, for the great help, and support he offered to me.

I shall always feel indebted to *prof. Dr. Seham Fahmy Badr*, Assistant prof. Of cardiology, Faculty of medicine, Tanta university, for her advice, encouragement, moral support, constructive criticism and accurate supervision.

I would like to express my appreciation and gratitude to *prof. Dr. Osama Abd-El- Aziz*, professor and Head of cardiology Faculty of medicine, Tanta University for his meticulous supervision, unlimited help, Valuable advice and instructions.

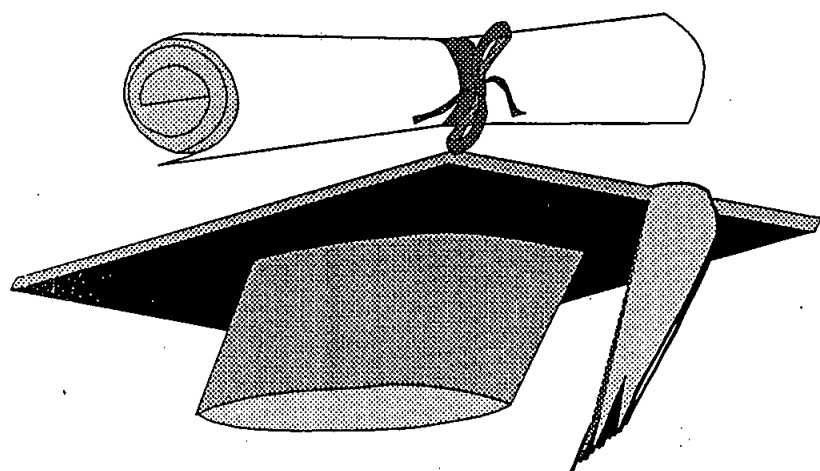
I would like to express my deepest gratitude and appreciation to *prof. Dr. Said -Shalaby*, Assistant Prof. Of Cardiology, Faculty of Medicine, Monofia University for his valuable Supervision, Meticulous guidance, Kean interest and the golden advices derived from his wide experience. To him, I'm truly thankful for his precious help which made this work an existing reality.

Finally, great thanks to every one who learned, advised, helped and supported me to fulfil this thesis.

Introduction	1
Aim of the work	2
Review of literature:	
• Left ventricular diastolic performance:	3
*Definition and significance	4
*Phases of Diastole	5-9
*Determinants of LV Diastolic performance.	9-17
• Methods for acquiring data on LV Diastolic performance.	18-22
*Doppler Echo Cardiographic evaluation of Diastolic dysfunction	23
*Rational for use of Doppler to assess diastolic function.	24-28
*Validation of Doppler transmitral filling Rates.	29-30
*Doppler descriptors of diastolic dysfunction	30-37
*Clinical application of Doppler to assess Diastolic dysfunction.	38-41
• Specific pathologic conditions:	42-48
Abnormalities of diastolic function and potential treatments.	42-48
• Future Directions.	48-49
• <i>DOPPLER TISSUE IMAGING.</i>	50
*Definition.	50
*Historical Review	51,52
*Technical principles of Doppler tissue Imaging.	53-55

*Modes of Doppler tissue.	56-64
*Normal pattern of Doppler tissue Imaging	65-67
*Analysis of velocity vector according to the imaging view:	68-80
*Assessment of the cardiac physiology by Doppler tissue imaging.	81-84
*Assessment of the cardiac function with DTI.	85-91
*Clinical applications of Doppler tissue Imaging.	92-108
*Limitation of Doppler tissue imaging.	109-110
Subjects and methods	111-117
Results	118-138
Discussion	139-150
Summary and conclusion	151-156
References	157-182
Arabic summary	

INTRODUCTION



INTRODUCTION

INTRODUCTION

Diastolic dysfunction is the primary mechanism responsible for dyspnea in patients with heart failure irrespective of the presence or severity of systolic dysfunction ⁽¹⁾.

Doppler echocardiography has become the non-invasive technique of choice for the evaluation of diastolic function ⁽²⁾.

However, current methods are limited by the dependence of transmitral flow velocity and the isovolumic relaxation time (IVRT) on left ventricular relaxation and left atrial pressure. ⁽³⁾

Increases in left atrial pressure override the effects of impaired relaxation, resulting frequently in a pseudonormalization of the transmitral velocity .

The differentiation of the pseudonormal pattern from the normal pattern is currently done by data derived from clinical and echocardiographic findings that suggest the presence of impaired L.V. relaxation or by inspection of the pulmonary vein velocity . ⁽⁴⁾

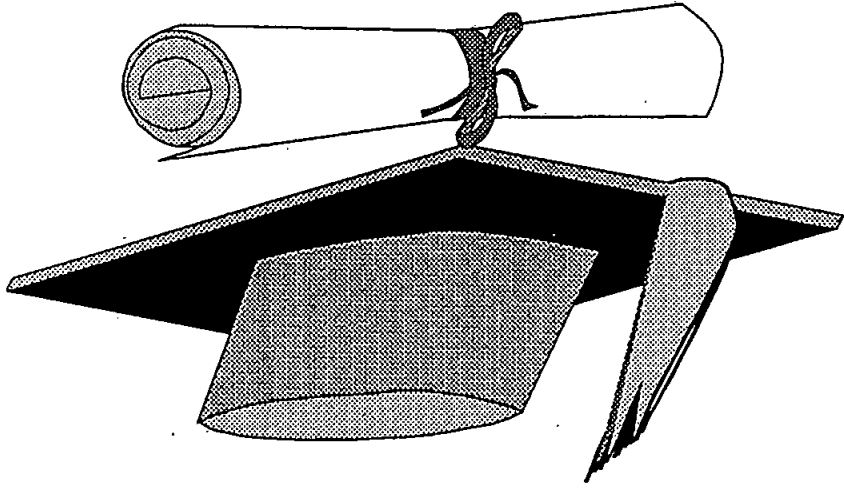
Doppler tissue imaging is a new ultrasound modality that records systolic and diastolic velocities within the myocardium. Therefore, it can be used to quantitate the velocity of mitral annulus displacement during systole and diastole. ⁽⁵⁾

AIM

OF

THE

WORK



AIM OF THE WORK